TOPOGRAPHICAL ANATOMY OF THE LOWER LIMB

Václav Báča, David Kachlík
Tereza Smržová, Martin Holek, Katarina Hubčíkova, Radek Jakša

Department of Anatomy, Third Faculty of Medicine,
Charles University in Prague

supported by grant FRVS 1101/2008/F3

FORAMEN ISCHIADICUM MAJUS

(greater sciatic foramen)

BORDERS:

VENTRO-LATERAL:
incisura ischiadica major ossis coxae

DORSO-MEDIAL:
lig. sacrotuberale

CAUDAL:
lig. sacrospinale

CONTENT:

m. piriformis

divides the foramen into two following parts

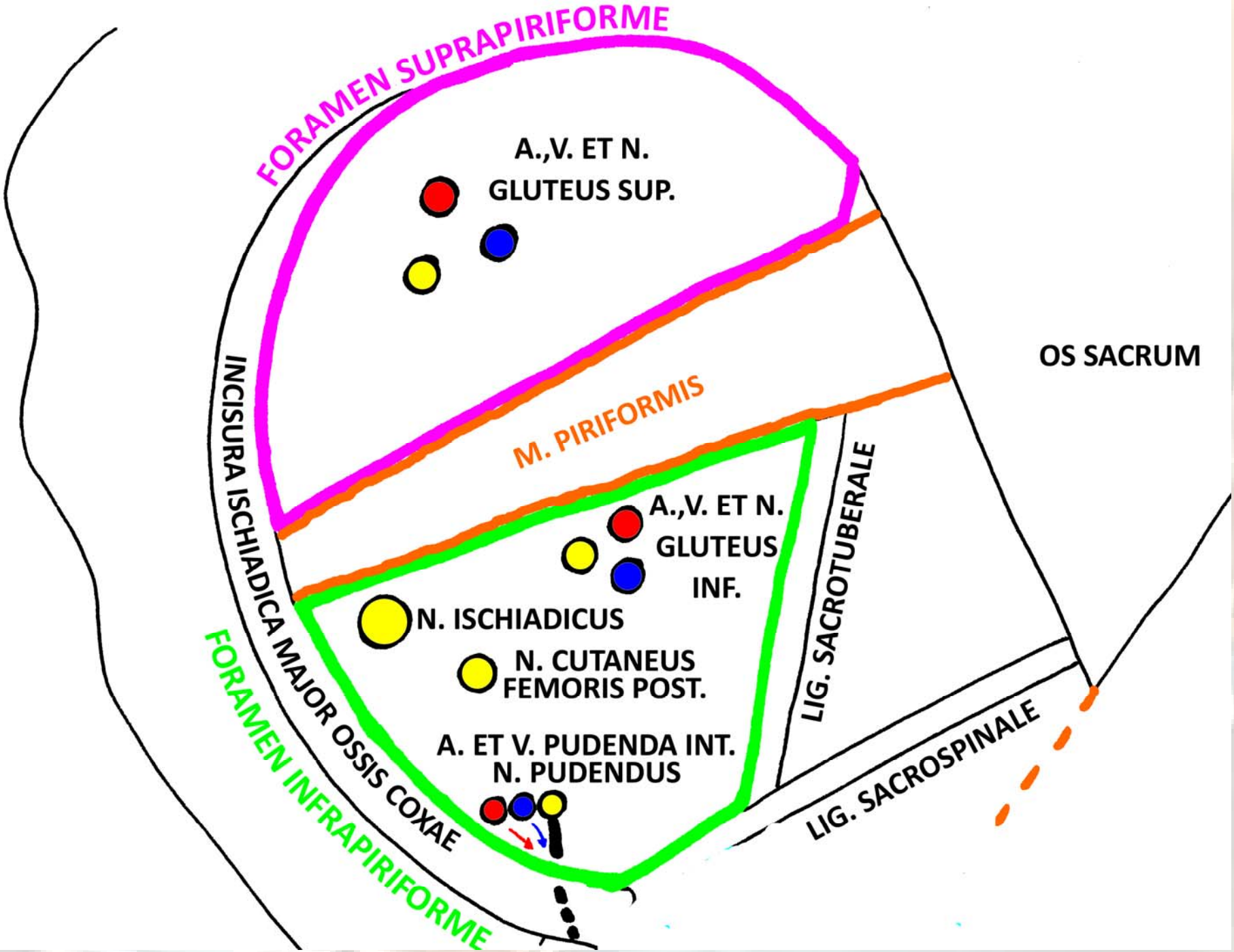
FORAMEN SUPRAPIRIFORME
A.,V. ET N.
GLUTEUS SUP.
OS SACRUM
M. PIRIFORMIS
INCISURA ISCHIADICA MAJOR OSSIS COXAE
A.,V. ET N.
GLUTEUS
INF.
N. ISCHIADICUS
N. CUTANEUS
FEMORIS POST.
LIG. SACROTUBERALE
FORAMEN INFRAPIRIFORME
A. ET V. PUDENDA INT.
N. PUDENDUS
LIG. SACROSPINALE

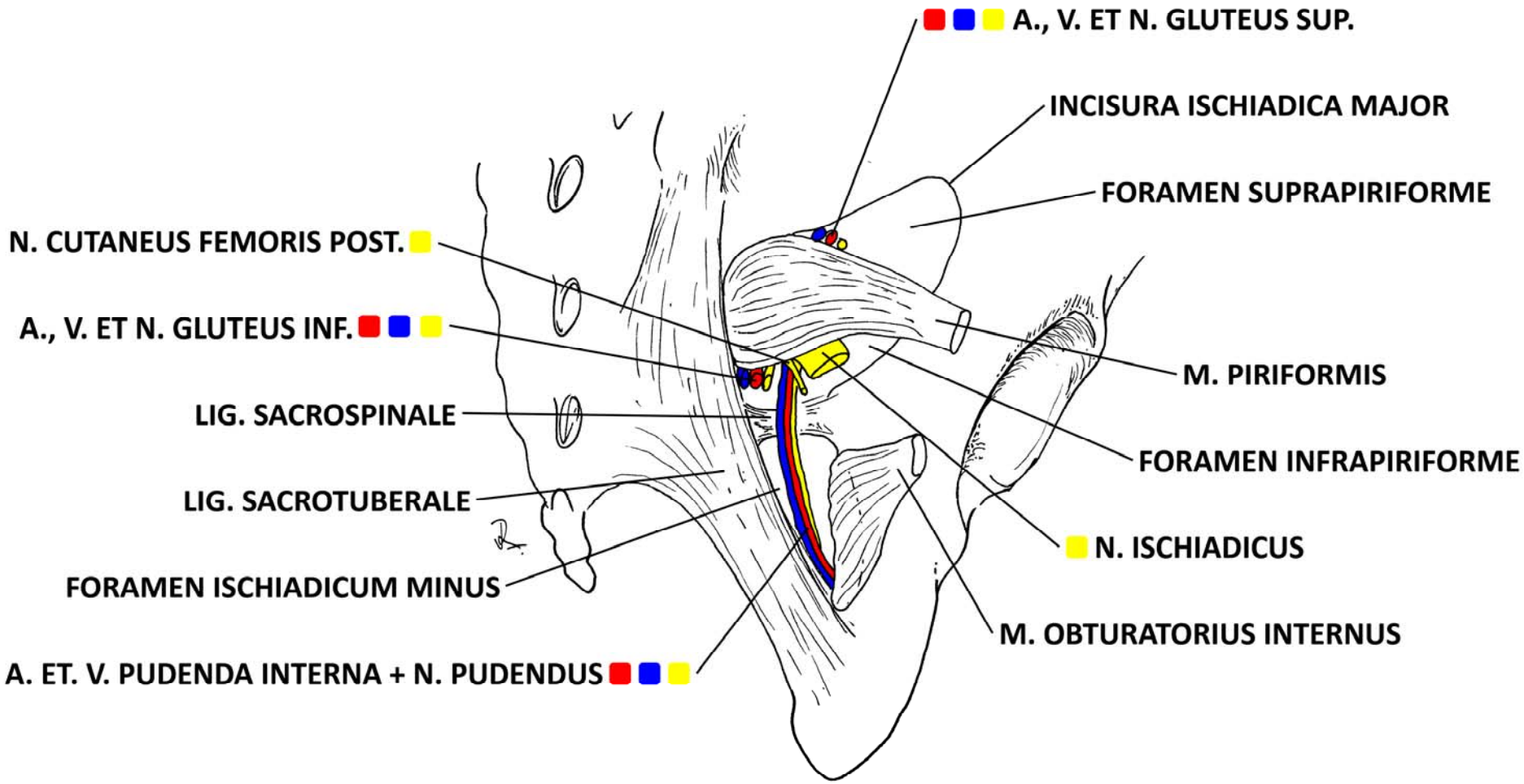
A., V. ET N. GLUTEUS SUP.
INCISURA ISCHIADICA MAJOR
FORAMEN SUPRAPIRIFORME
N. CUTANEUS FEMORIS POST.
A., V. ET N. GLUTEUS INF.
M. PIRIFORMIS
LIG. SACROSPINALE
FORAMEN INFRAPIRIFORME
LIG. SACROTUBERALE
N. ISCHIADICUS
FORAMEN ISCHIADICUM MINUS
M. OBTURATORIUS INTERNUS
A. ET. V. PUDENDA INTERNA + N. PUDENDUS

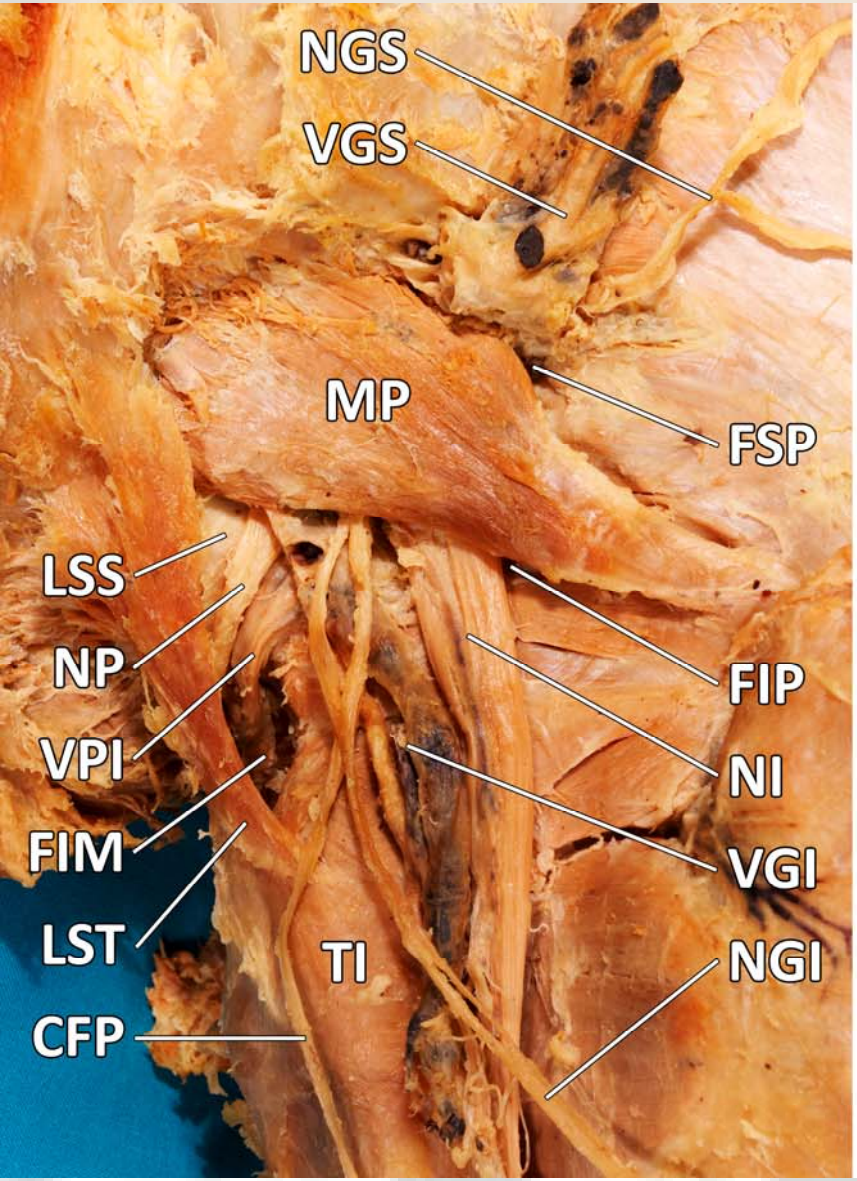

NGS - N. GLUTEUS SUPERIOR
VGS - VASA GLUTEA SUPERIORA
MP - M. PIRIFORMIS
LSS - LIG. SACROSPINALE
NP - N. PUDENDUS
VPI - VASA PUDENDA INTERNA
FIM - FORAMEN ISCHIADICUM MINUS
LST - LIG. SACROTUBERALE
CFP - N. CUTANEUS FEMORIS POST.
TI - TUBER ISCHIADICUM
FSP - FORAMEN SUPRAPIRIFORME
FIP - FORAMEN INFRAPIRIFORME
NI - N. ISCHIADICUS
VGI - VASA GLUTEA INFERIORA
NGI - N. GLUTEUS INFERIOR

FORAMEN SUPRAPIRIFORME

BORDERS:

VENTRO-LATERAL:
incisura ischiadica major ossis coxae

DORSO-MEDIAL:
lig. sacrotuberale

CAUDAL:
m. piriformis

CONTENT:

nervus gluteus sup.

arteria glutea sup.

vena glutea sup.

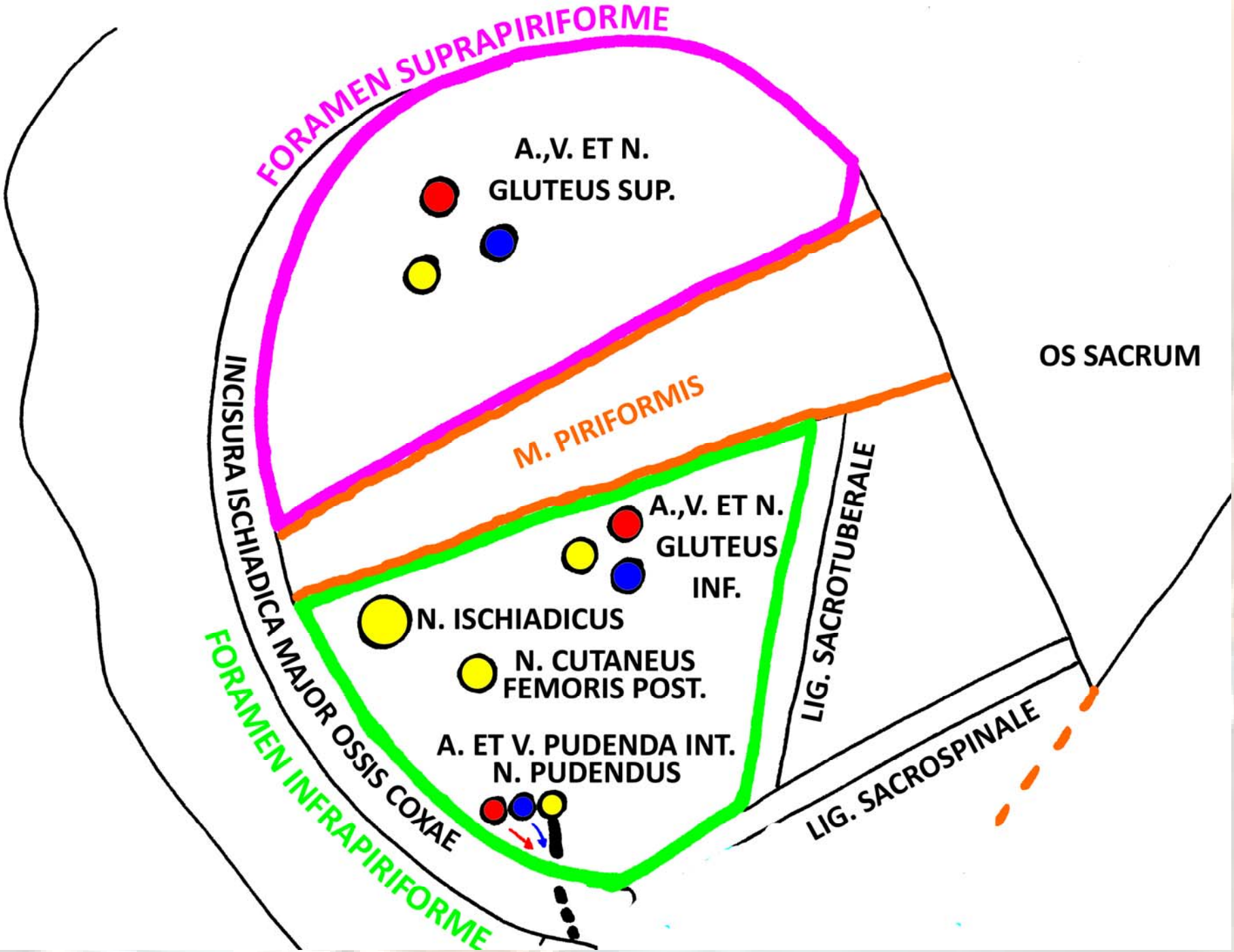
FORAMEN SUPRAPIRIFORME
A.,V. ET N.
GLUTEUS SUP.
OS SACRUM
M. PIRIFORMIS
INCISURA ISCHIADICA MAJOR OSSIS COXAE
A.,V. ET N.
GLUTEUS
INF.
N. ISCHIADICUS
N. CUTANEUS
FEMORIS POST.
LIG. SACROTUBERALE
FORAMEN INFRAPIRIFORME
A. ET V. PUDENDA INT.
N. PUDENDUS
LIG. SACROSPINALE

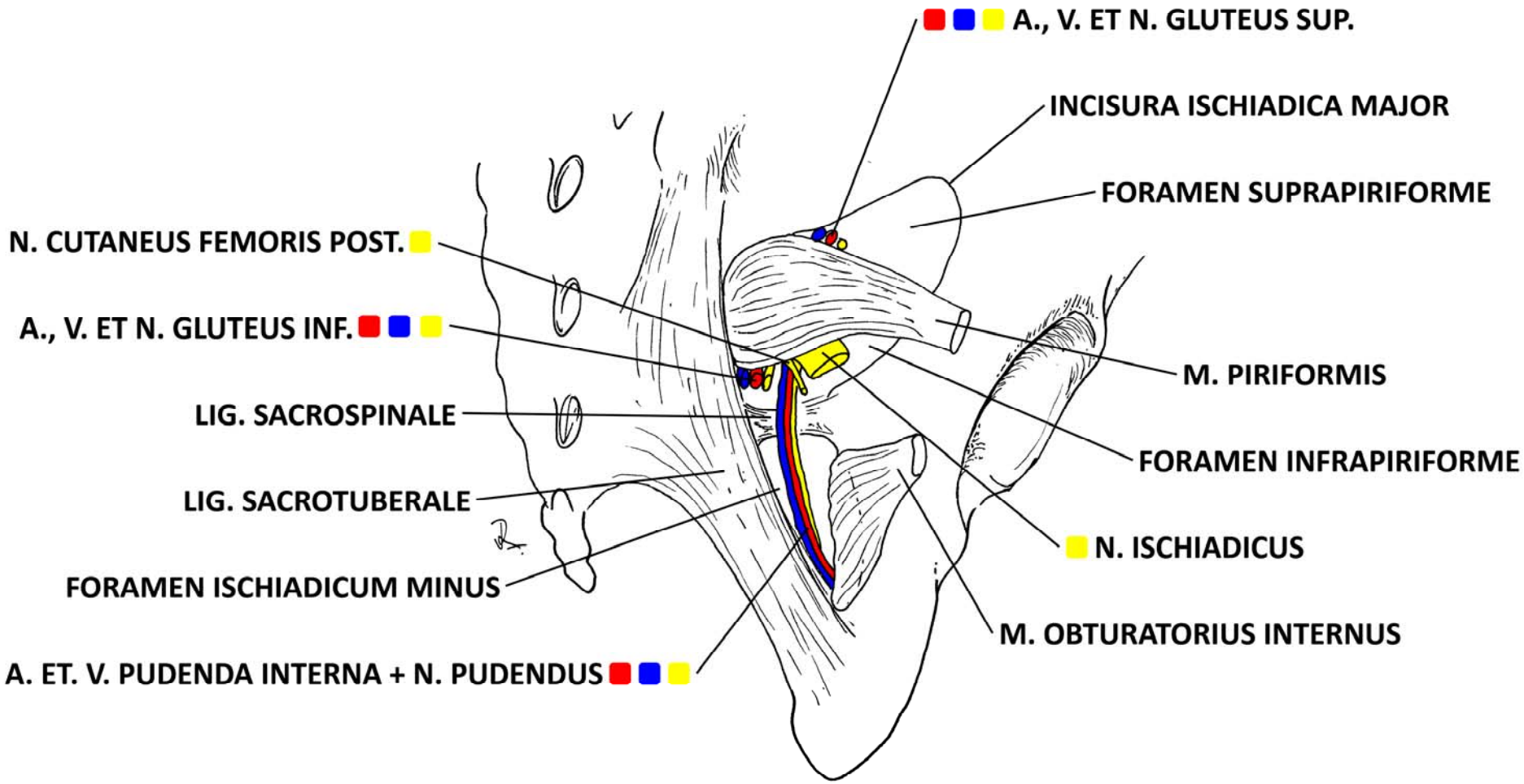
A., V. ET N. GLUTEUS SUP.
INCISURA ISCHIADICA MAJOR
FORAMEN SUPRAPIRIFORME
N. CUTANEUS FEMORIS POST.
A., V. ET N. GLUTEUS INF.
M. PIRIFORMIS
LIG. SACROSPINALE
FORAMEN INFRAPIRIFORME
LIG. SACROTUBERALE
N. ISCHIADICUS
FORAMEN ISCHIADICUM MINUS
M. OBTURATORIUS INTERNUS
A. ET. V. PUDENDA INTERNA + N. PUDENDUS

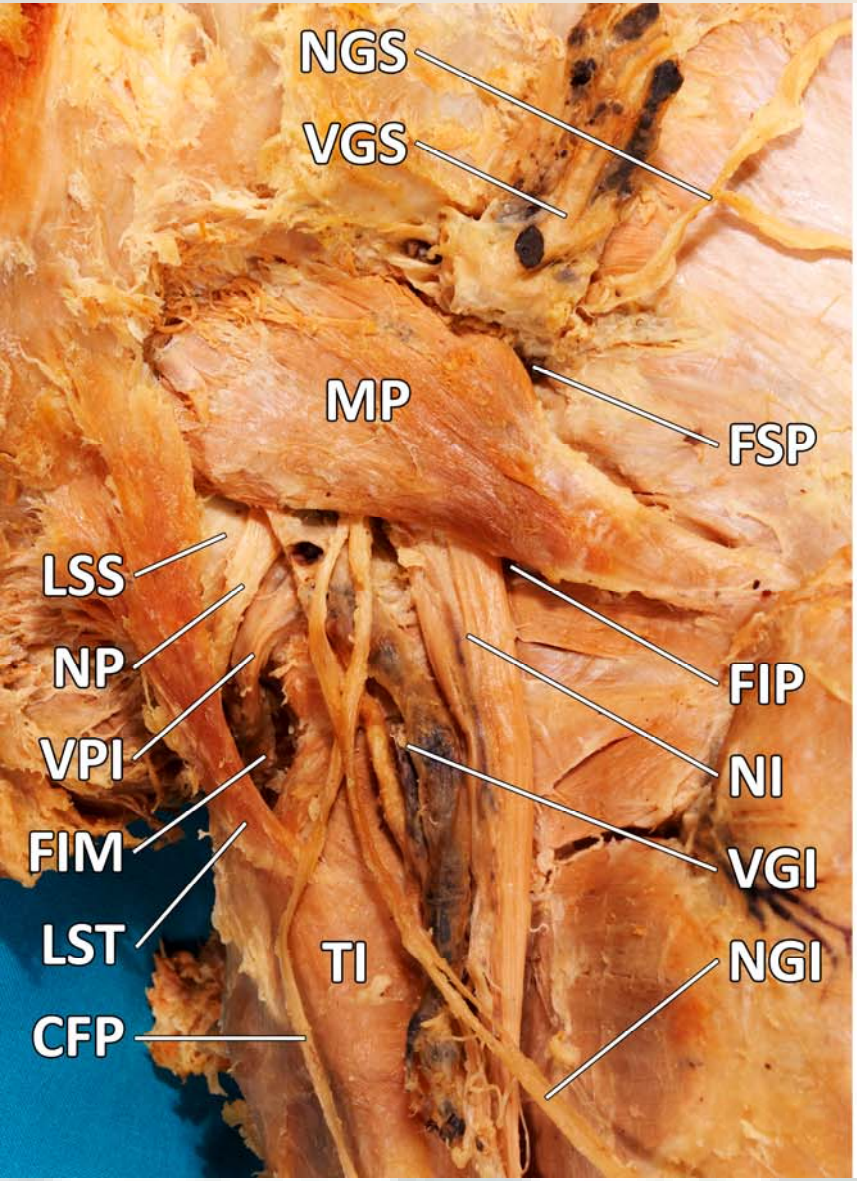

NGS - N. GLUTEUS SUPERIOR
VGS - VASA GLUTEA SUPERIORA
MP - M. PIRIFORMIS
LSS - LIG. SACROSPINALE
NP - N. PUDENDUS
VPI - VASA PUDENDA INTERNA
FIM - FORAMEN ISCHIADICUM MINUS
LST - LIG. SACROTUBERALE
CFP - N. CUTANEUS FEMORIS POST.
TI - TUBER ISCHIADICUM
FSP - FORAMEN SUPRAPIRIFORME
FIP - FORAMEN INFRAPIRIFORME
NI - N. ISCHIADICUS
VGI - VASA GLUTEA INFERIORA
NGI - N. GLUTEUS INFERIOR

FORAMEN INFRAPIRIFORME

BORDERS:

CRANIAL:
m. piriformis

VENTRO-LATERAL:
incisura ischiadica major ossis coxae

DORSO-MEDIAL:
lig. sacrotuberale

CAUDAL:
lig. sacrospinale

CONTENT:

nervus ischiadicus

nervus pudendus

nervus gluteus inf.

nervus cutaneus femoris post.

arteria glutea inf.

vena glutea inf.

arteria pudenda int.

vena pudenda int.

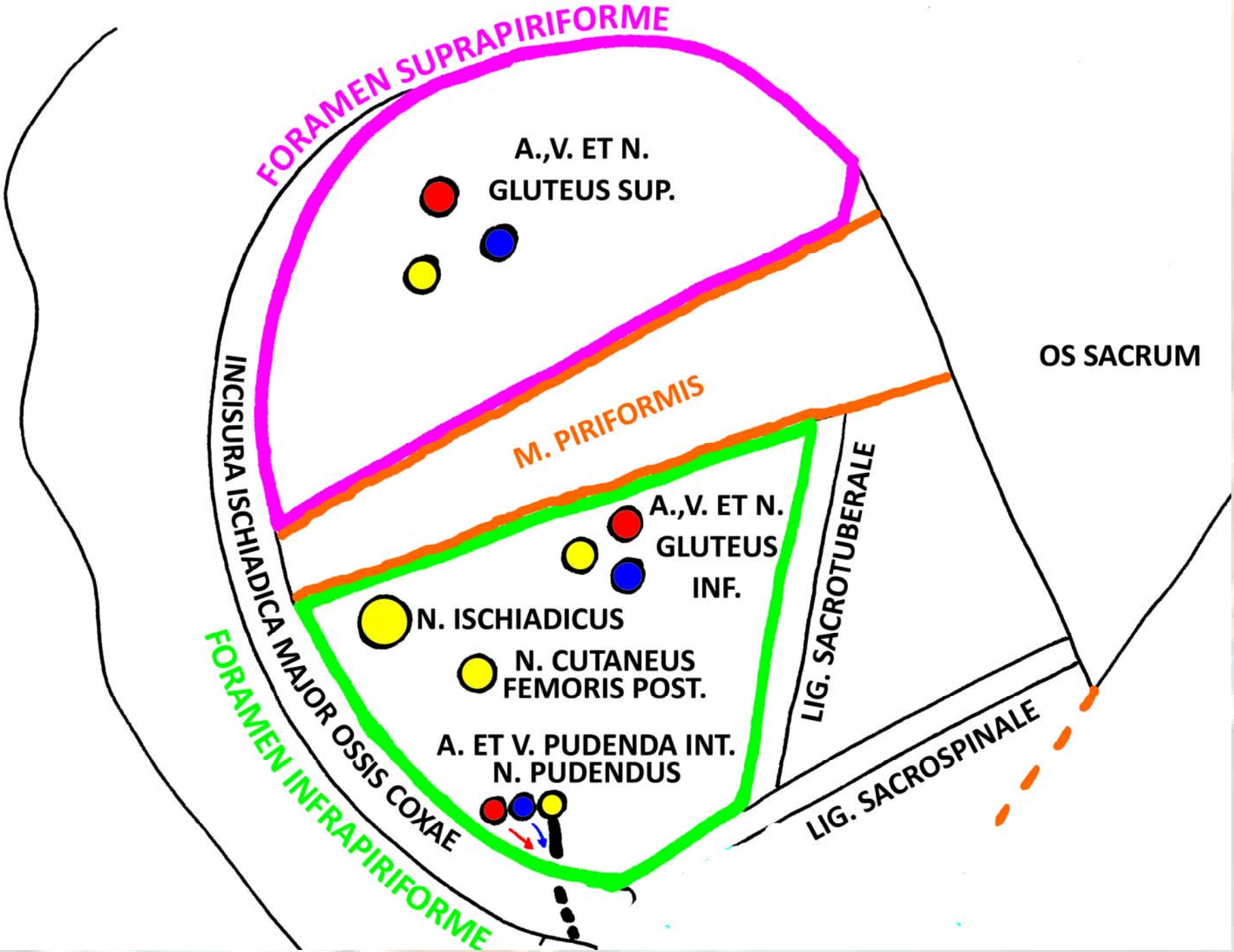
FORAMEN SUPRAPIRIFORME
A.,V. ET N.
GLUTEUS SUP.
OS SACRUM
M. PIRIFORMIS
INCISURA ISCHIADICA MAJOR OSSIS COXAE
A.,V. ET N.
GLUTEUS
INF.
N. ISCHIADICUS
N. CUTANEUS
FEMORIS POST.
LIG. SACROTUBERALE
FORAMEN INFRAPIRIFORME
A. ET V. PUDENDA INT.
N. PUDENDUS
LIG. SACROSPINALE

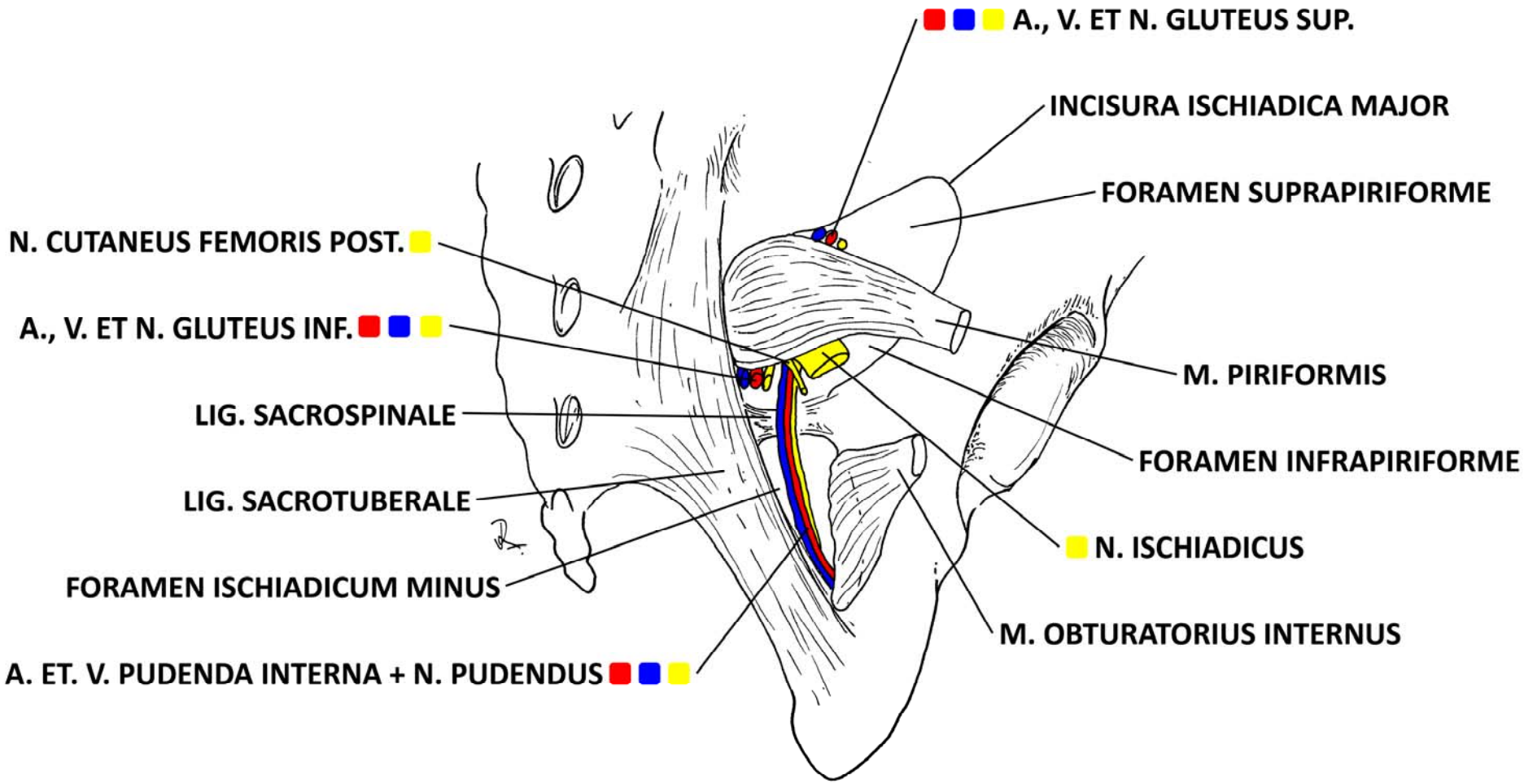
A., V. ET N. GLUTEUS SUP.
INCISURA ISCHIADICA MAJOR
FORAMEN SUPRAPIRIFORME
N. CUTANEUS FEMORIS POST.
A., V. ET N. GLUTEUS INF.
M. PIRIFORMIS
LIG. SACROSPINALE
FORAMEN INFRAPIRIFORME
LIG. SACROTUBERALE
N. ISCHIADICUS
FORAMEN ISCHIADICUM MINUS
M. OBTURATORIUS INTERNUS
A. ET. V. PUDENDA INTERNA + N. PUDENDUS

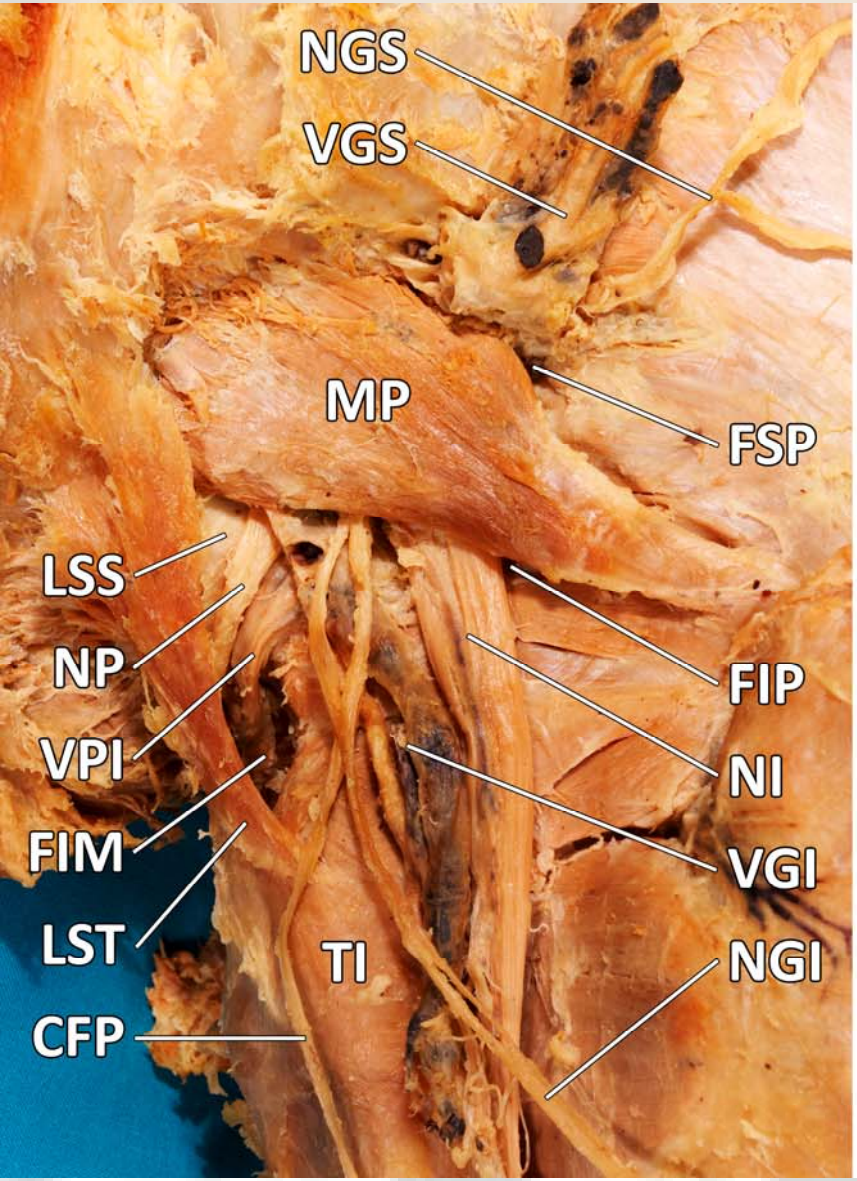

NGS - N. GLUTEUS SUPERIOR
VGS - VASA GLUTEA SUPERIORA
MP - M. PIRIFORMIS
LSS - LIG. SACROSPINALE
NP - N. PUDENDUS
VPI - VASA PUDENDA INTERNA
FIM - FORAMEN ISCHIADICUM MINUS
LST - LIG. SACROTUBERALE
CFP - N. CUTANEUS FEMORIS POST.
TI - TUBER ISCHIADICUM
FSP - FORAMEN SUPRAPIRIFORME
FIP - FORAMEN INFRAPIRIFORME
NI - N. ISCHIADICUS
VGI - VASA GLUTEA INFERIORA
NGI - N. GLUTEUS INFERIOR

FORAMEN ISCHIADICUM MINUS

(lesser sciatic foramen)

BORDERS:

VENTRO-LATERAL:

incisura ischiadica minor ossis coxae

DORSO-MEDIAL:

lig. sacrotuberale

CONTENT:

nervus pudendus

arteria pudenda int.

vena pudenda int.

m. obturatorius internus

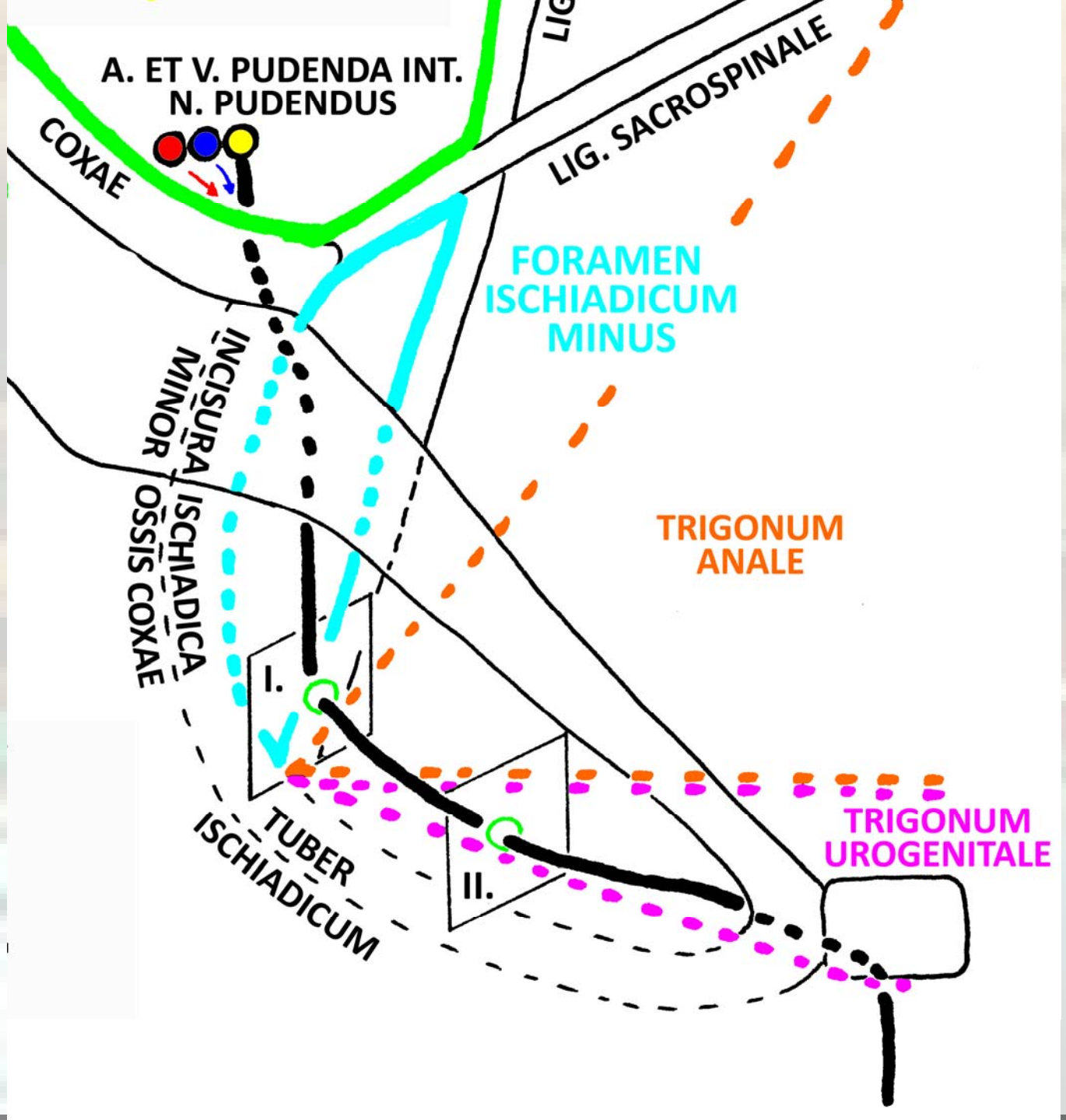
A. ET V. PUDENDA INT.
N. PUDENDUS
COXAE
LIG. SACROSPINALE
FORAMEN
ISCHIADICUM
MINUS
INCISURA ISCHIADICA MINOR
OSSIS COXAE
TRIGONUM
ANALE
I.
II.
TUBER
ISCHIADICUM
TRIGONUM
UROGENITALE

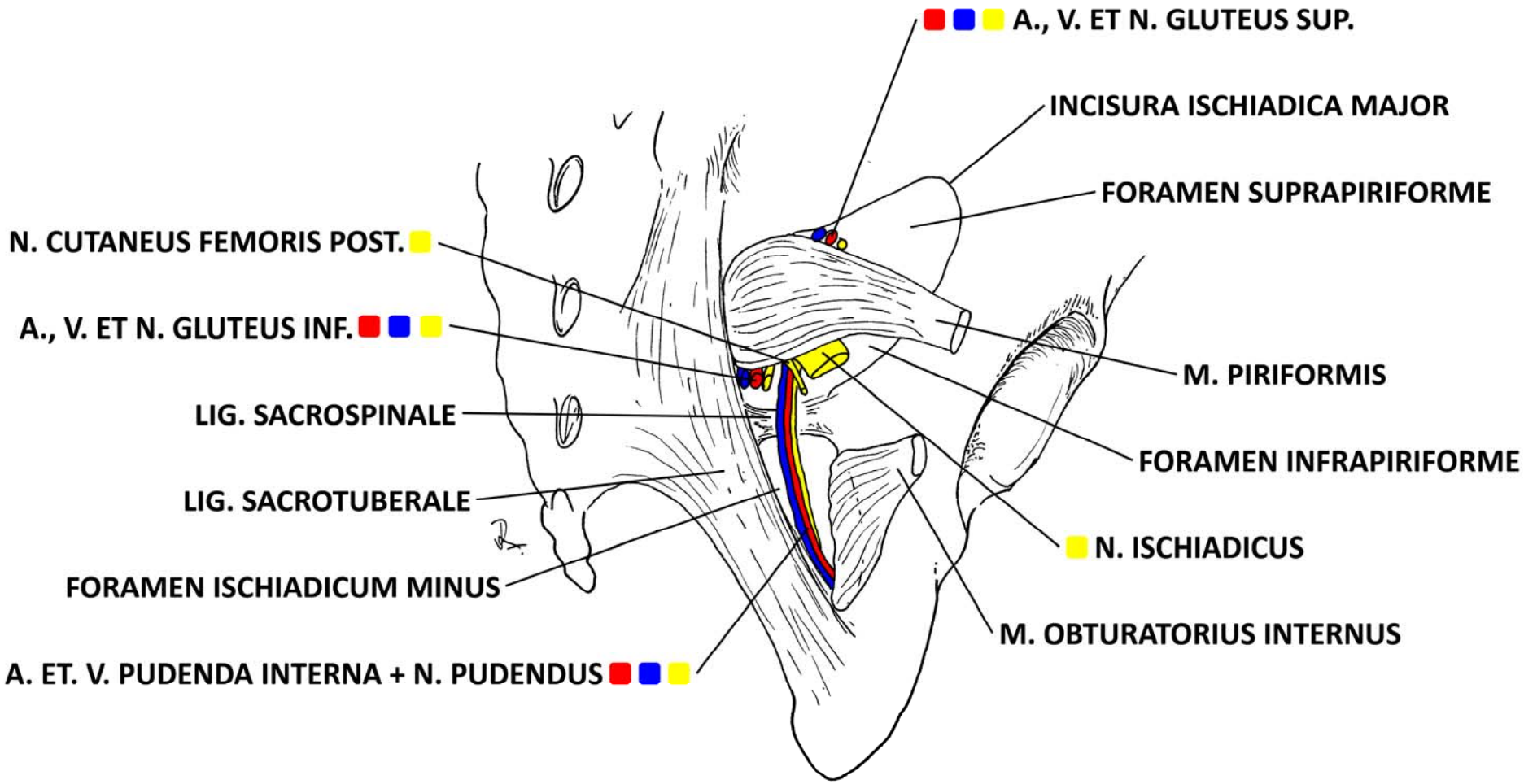
A., V. ET N. GLUTEUS SUP.
INCISURA ISCHIADICA MAJOR
FORAMEN SUPRAPIRIFORME
N. CUTANEUS FEMORIS POST.
A., V. ET N. GLUTEUS INF.
M. PIRIFORMIS
LIG. SACROSPINALE
FORAMEN INFRAPIRIFORME
LIG. SACROTUBERALE
N. ISCHIADICUS
FORAMEN ISCHIADICUM MINUS
M. OBTURATORIUS INTERNUS
A. ET. V. PUDENDA INTERNA + N. PUDENDUS

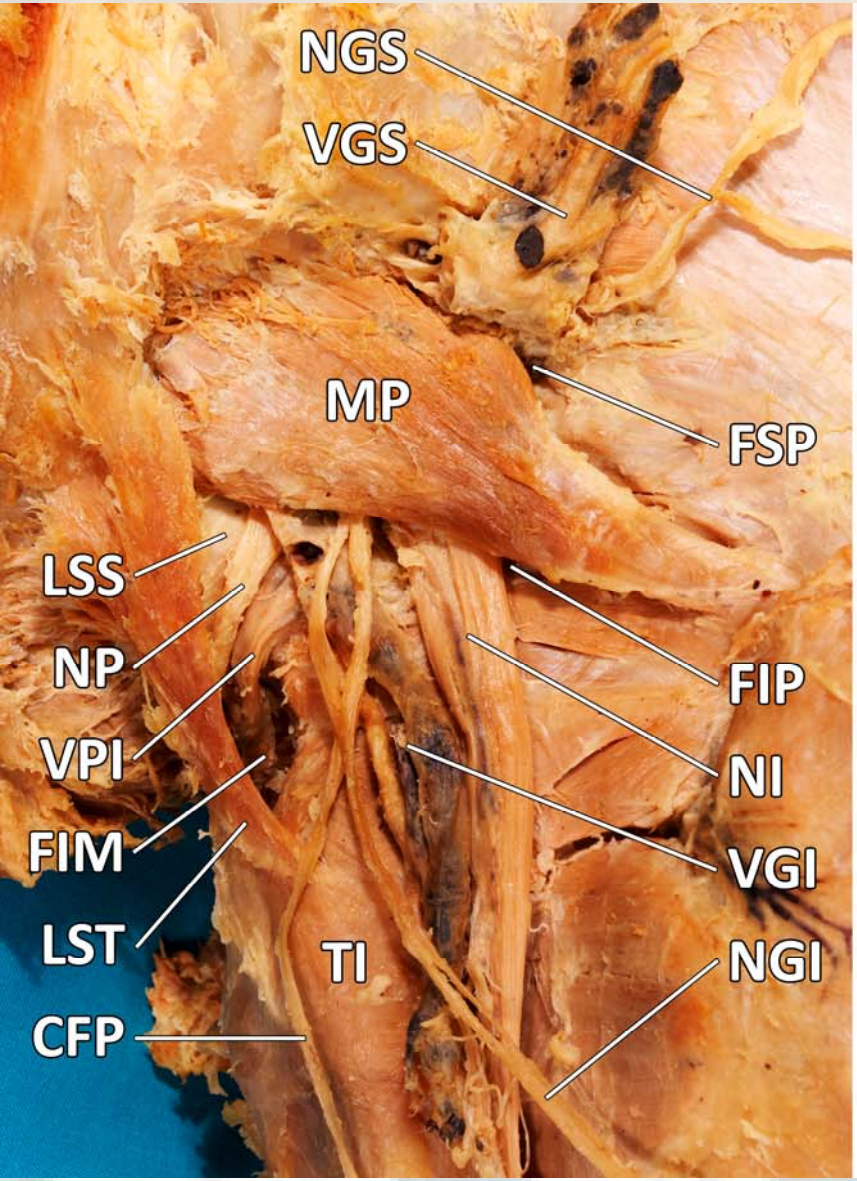

NGS - N. GLUTEUS SUPERIOR
VGS - VASA GLUTEA SUPERIORA
MP - M. PIRIFORMIS
LSS - LIG. SACROSPINALE
NP - N. PUDENDUS
VPI - VASA PUDENDA INTERNA
FIM - FORAMEN ISCHIADICUM MINUS
LST - LIG. SACROTUBERALE
CFP - N. CUTANEUS FEMORIS POST.
TI - TUBER ISCHIADICUM
FSP - FORAMEN SUPRAPIRIFORME
FIP - FORAMEN INFRAPIRIFORME
NI - N. ISCHIADICUS
VGI - VASA GLUTEA INFERIORA
NGI - N. GLUTEUS INFERIOR

CANALIS OBTURATORIUS

BORDERS:

membrana obturatoria covering foramen obturatum is missing in the area of sulcus obturatorius creating the canal

CONTENT:

nervus obturatorius

vena obturatoria

arteria obturatoria

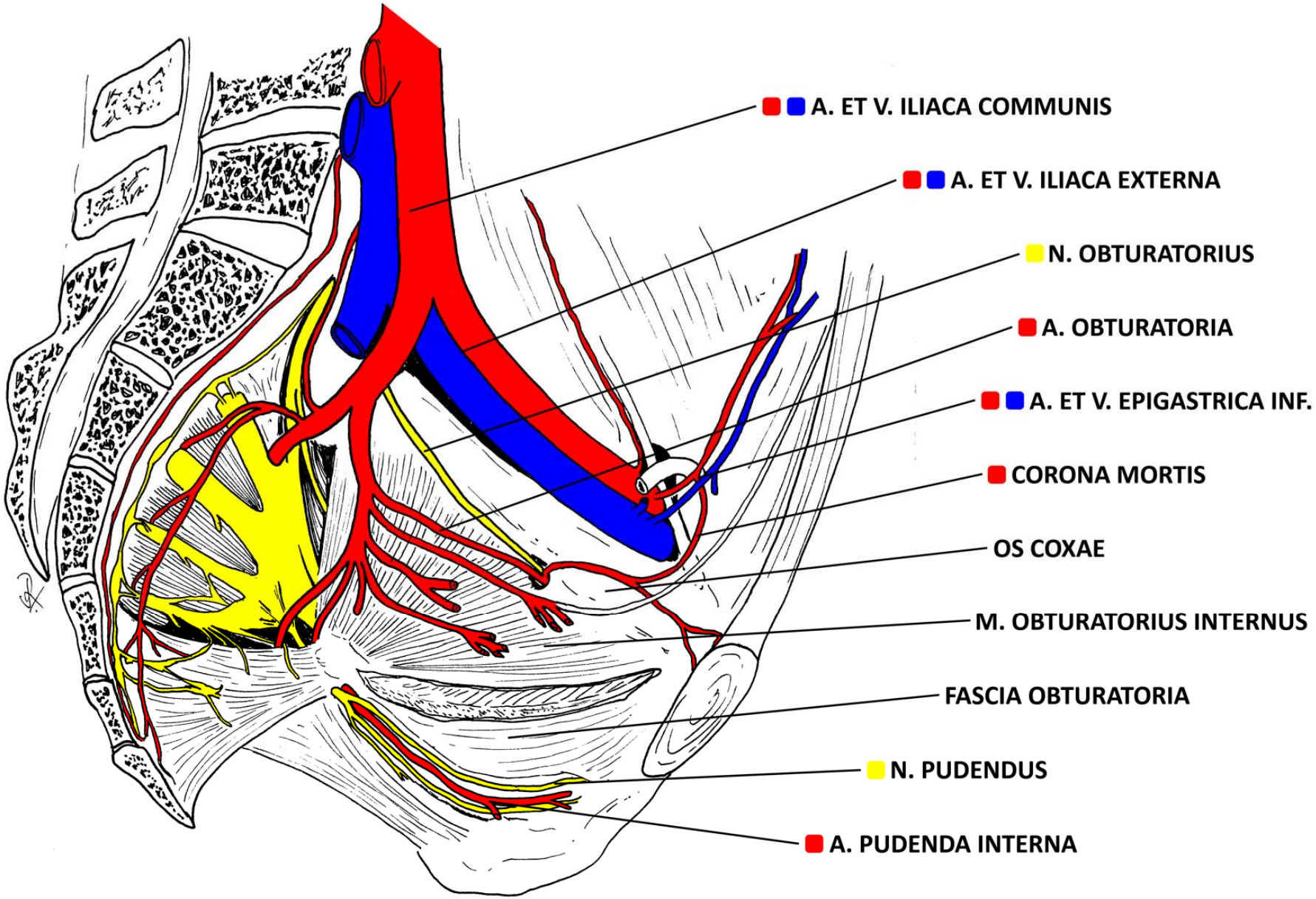
A. ET V. ILIACA COMMUNIS
A. ET V. ILIACA EXTERNA
N. OBTURATORIUS
A. OBTURATORIA
A. ET V. EPIGASTRICA INF.
CORONA MORTIS
OS COXAE
M. OBTURATORIUS INTERNUS
FASCIA OBTURATORIA
N. PUDENDUS
A. PUDENDA INTERNA

LACUNA VASORUM

(vascular space)

separated from pelvis with femoral septum

BORDERS:

VENTRAL:
lig. inguinale */Pouparti, Vesalii, Fallopii/*

LATERAL:
arcus iliopectineus

MEDIAL
lig. lacunare */Gimbernati/*

DORSAL:

lig. pectineale */Cooperi/* + os coxae

CONTENT:

nodus lymph. inguinalis prof.
/Cloqueti s. Rosenmülleri/

vena femoralis

arteria femoralis

ramus femoralis n. genitofemoralis

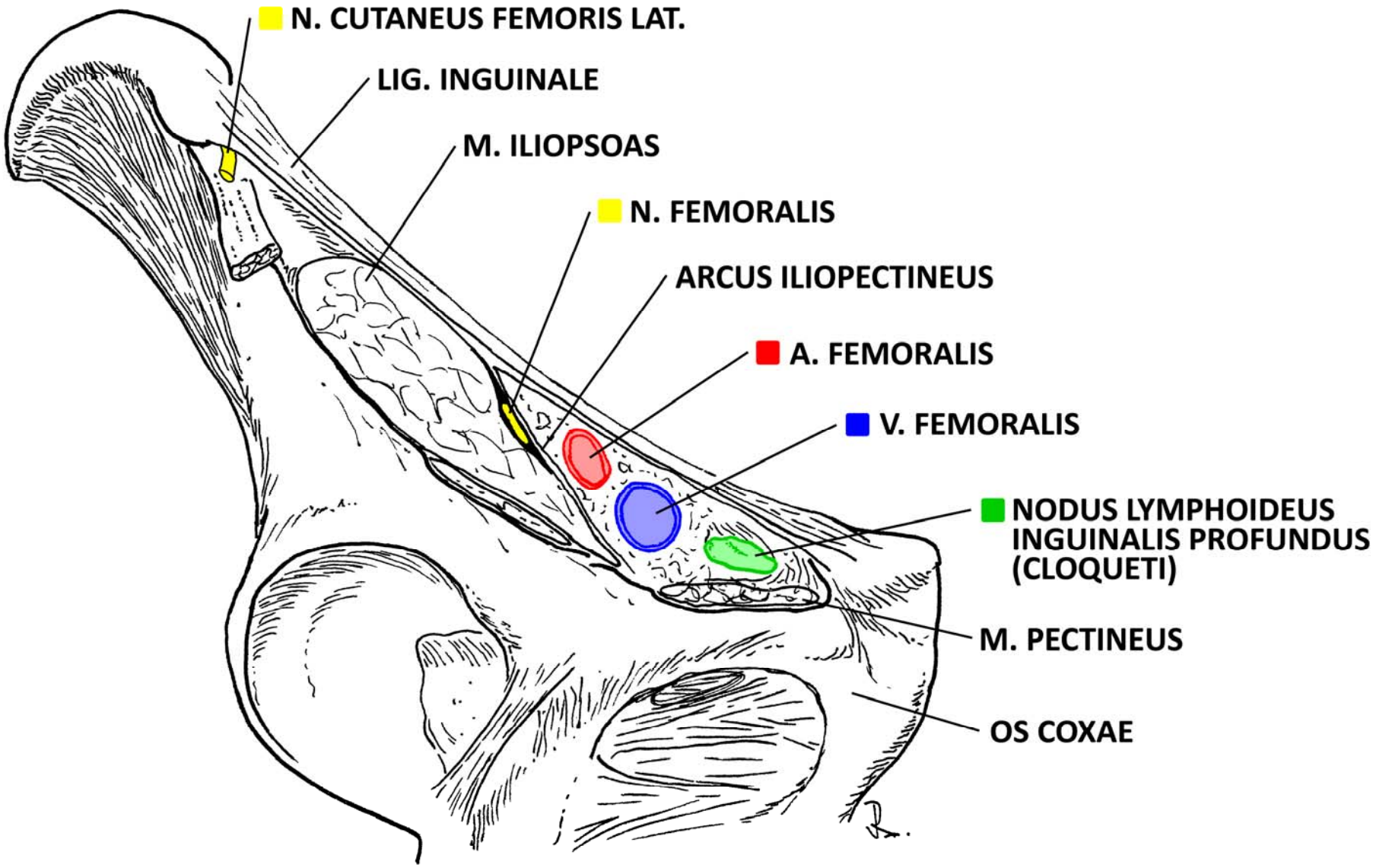
N. CUTANEUS FEMORIS LAT.
LIG. INGUINALE
M. ILIOPSOAS
N. FEMORALIS
ARCUS ILIOPECTINEUS
A. FEMORALIS
V. FEMORALIS
NODUS LYMPHOIDEUS INGUINALIS PROFUNDUS (CLOQUETI)
M. PECTINEUS
OS COXAE

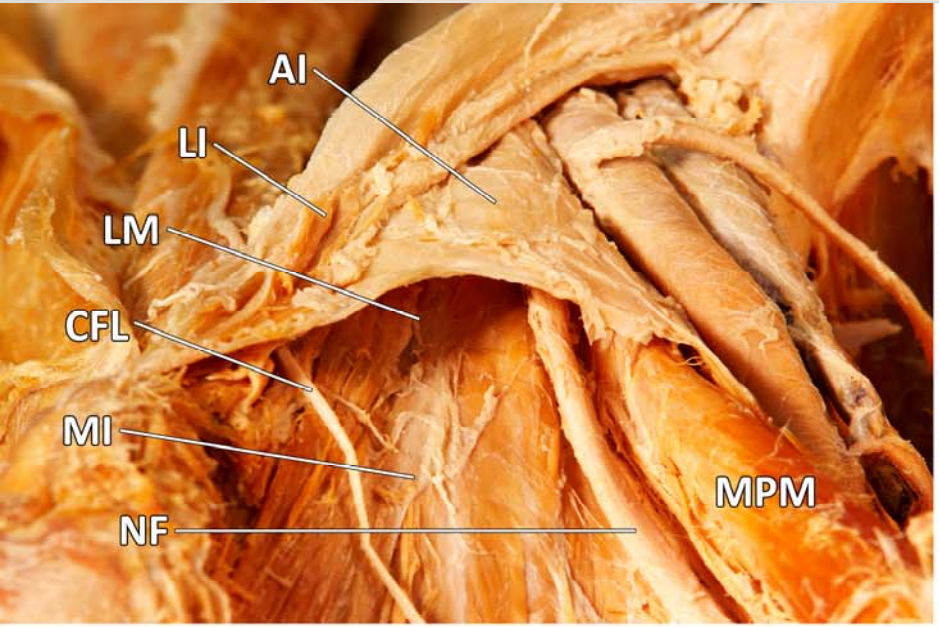

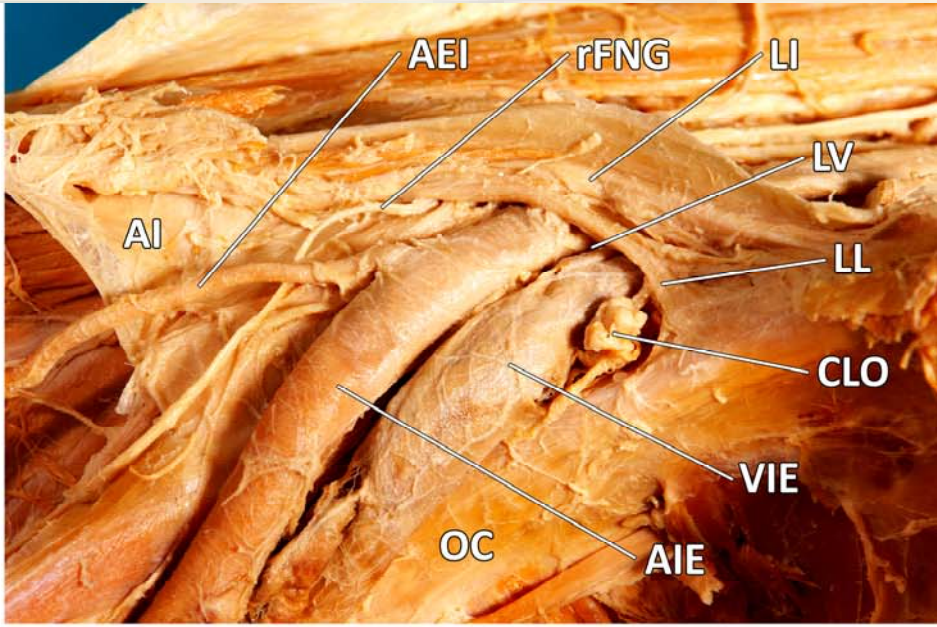

AI - ARCUS ILIOPECTINEUS
LI - LIG. INGUINALE
LM - LACUNA MUSCULORUM
CFL - N. CUTANEUS FEMORIS LAT.
MI - M. ILIACUS
NF - N. FEMORALIS
MPM - M. PSOAS MAJOR

AEI - A. EPIGASTRICA INF.
rFNG - R. FEMORALIS N. GENITOFEMORALIS
LV - LACUNA VASORUM
LL - LIG. LACUNARE
CLO - N. L. INGUINALIS PROFUNDUS (CLOQUETI)
VIE - V. ILIACA EXTERNA
AIE - A. ILIACA EXTERNA
OC - OS COXAE

CANALIS FEMORALIS

medial part of lacuna vasorum

BORDERS:

MEDIAL:

lig. lacunare */Gimbernati/*

LATERAL:

v. femoralis

aditus: anulus femoralis

exitus: hiatus saphenus

CONTENT:

nodus lymph. inguinalis prof.
/Cloqueti s. *Rosenmülleri/*

femoral hernia would occur here

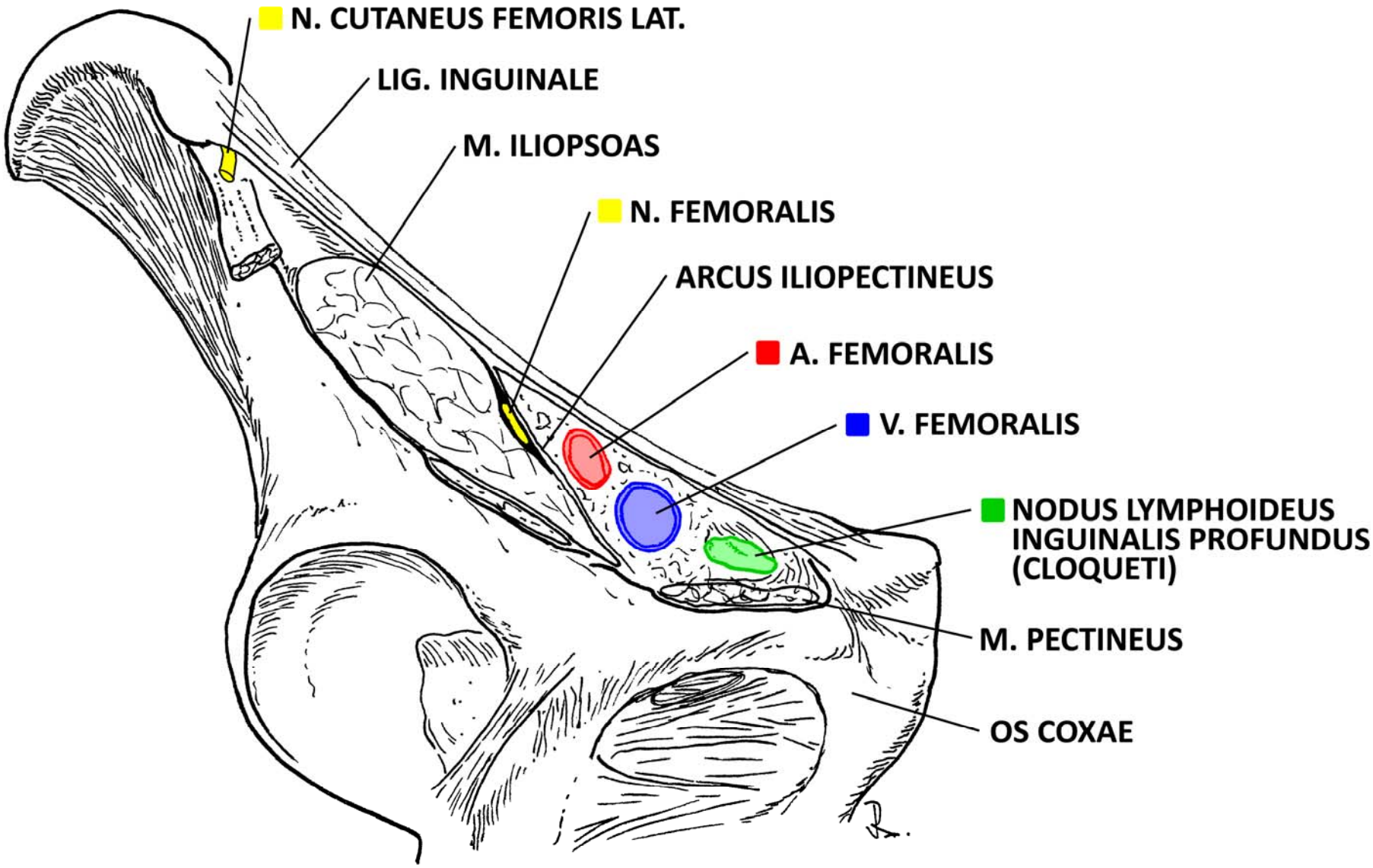
N. CUTANEUS FEMORIS LAT.
LIG. INGUINALE
M. ILIOPSOAS
N. FEMORALIS
ARCUS ILIOPECTINEUS
A. FEMORALIS
V. FEMORALIS
NODUS LYMPHOIDEUS INGUINALIS PROFUNDUS (CLOQUETI)
M. PECTINEUS
OS COXAE

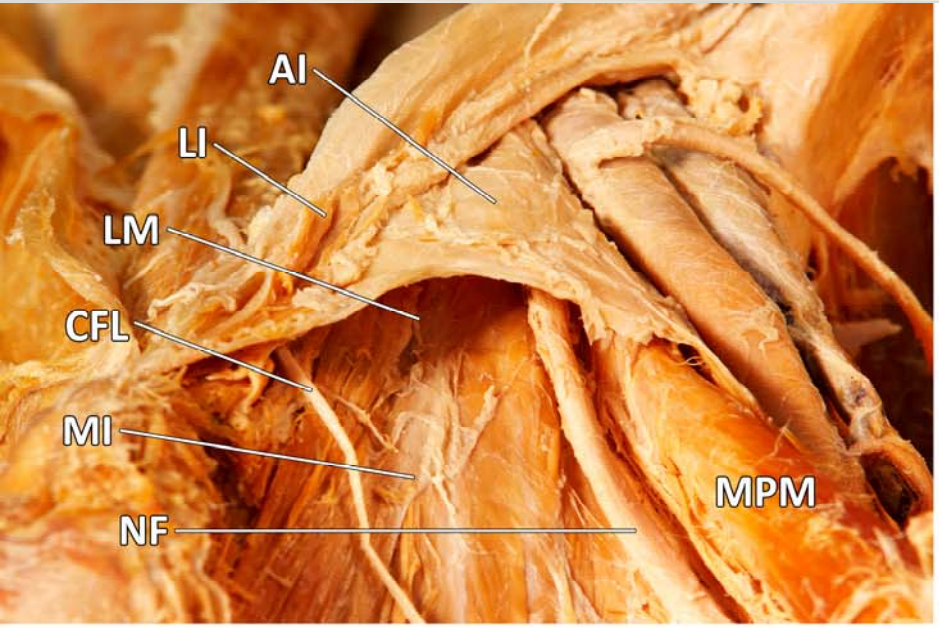

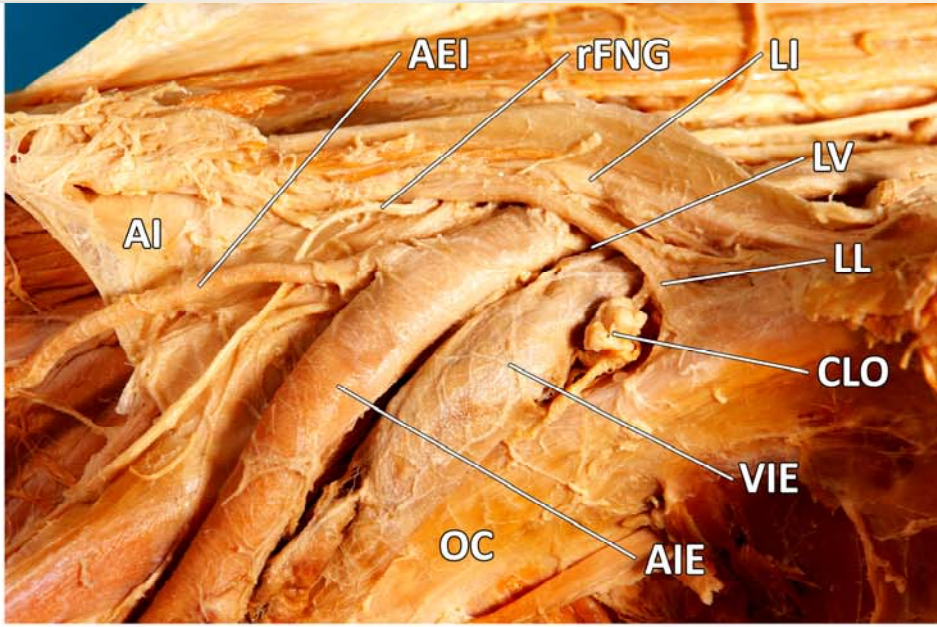

AI - ARCUS ILIOPECTINEUS
LI - LIG. INGUINALE
LM - LACUNA MUSCULORUM
CFL - N. CUTANEUS FEMORIS LAT.
MI - M. ILIACUS
NF - N. FEMORALIS
MPM - M. PSOAS MAJOR

AEI - A. EPIGASTRICA INF.
rFNG - R. FEMORALIS N. GENITOFEMORALIS
LV - LACUNA VASORUM
LL - LIG. LACUNARE
CLO - N. L. INGUINALIS PROFUNDUS (CLOQUETI)
VIE - V. ILIACA EXTERNA
AIE - A. ILIACA EXTERNA
OC - OS COXAE

LACUNA MUSCULORUM

(muscular space)

BORDERS:

VENTRAL:
lig. inguinale */Pouparti, Vesalii, Fallopii/*

DORSAL:
os coxae

MEDIAL:
arcus iliopectineus

CONTENT:

nervus femoralis

musculus iliopsoas

nervus cutaneus femoris lat.

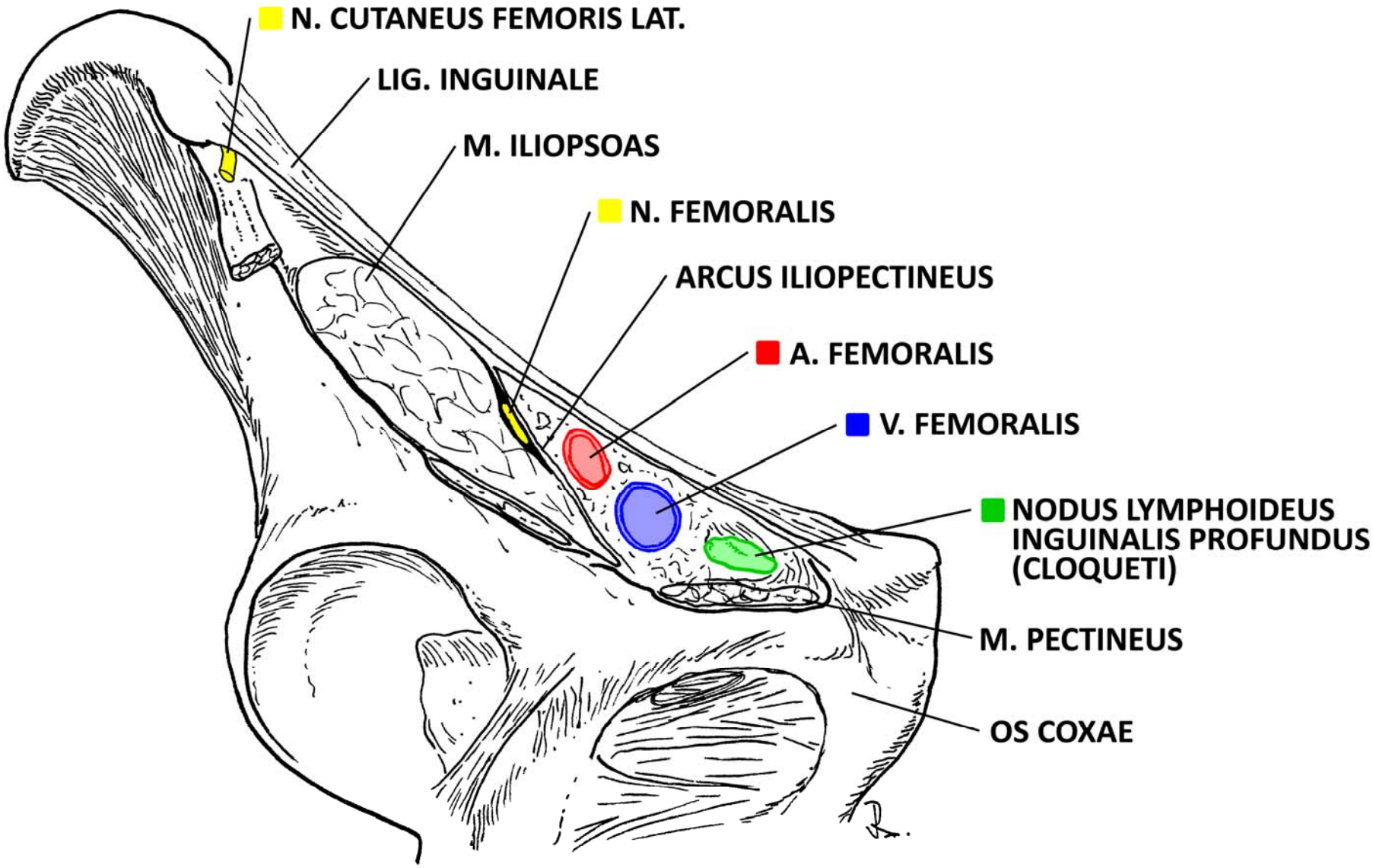
N. CUTANEUS FEMORIS LAT.
LIG. INGUINALE
M. ILIOPSOAS
N. FEMORALIS
ARCUS ILIOPECTINEUS
A. FEMORALIS
V. FEMORALIS
NODUS LYMPHOIDEUS INGUINALIS PROFUNDUS (CLOQUETI)
M. PECTINEUS
OS COXAE

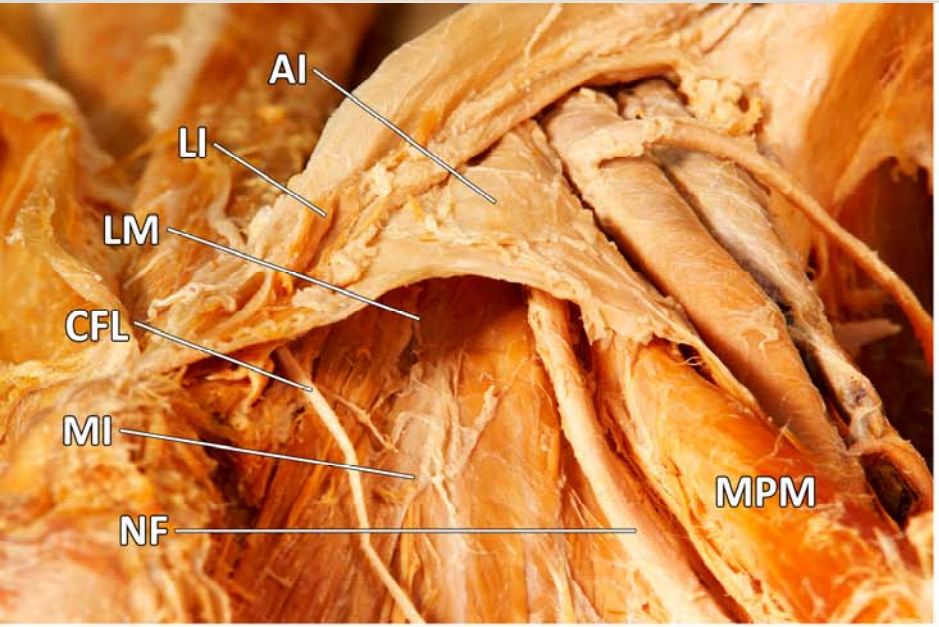

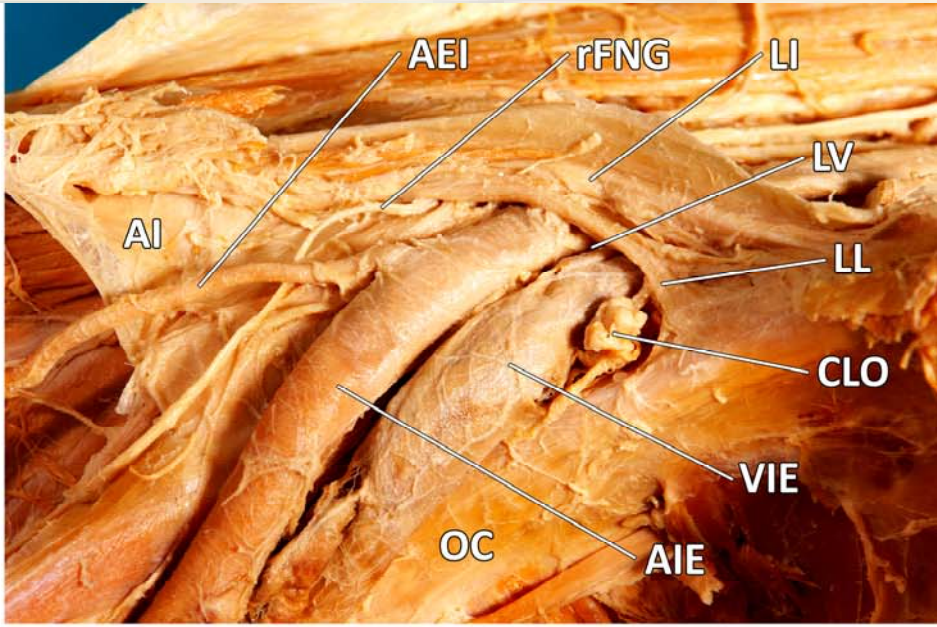

AI - ARCUS ILIOPECTINEUS
LI - LIG. INGUINALE
LM - LACUNA MUSCULORUM
CFL - N. CUTANEUS FEMORIS LAT.
MI - M. ILIACUS
NF - N. FEMORALIS
MPM - M. PSOAS MAJOR

AEI - A. EPIGASTRICA INF.
rFNG - R. FEMORALIS N. GENITOFEMORALIS
LV - LACUNA VASORUM
LL - LIG. LACUNARE
CLO - N. L. INGUINALIS PROFUNDUS (CLOQUETI)
VIE - V. ILIACA EXTERNA
AIE - A. ILIACA EXTERNA
OC - OS COXAE

CANALIS PUDENDALIS

/Alcock´s canal/

BORDERS:

in fossa ischioanalis, in fascia at the mediocaudal border of m. obturator internus

CONTENT:

nervus pudendus

vena pudenda interna

arteria pudenda interna

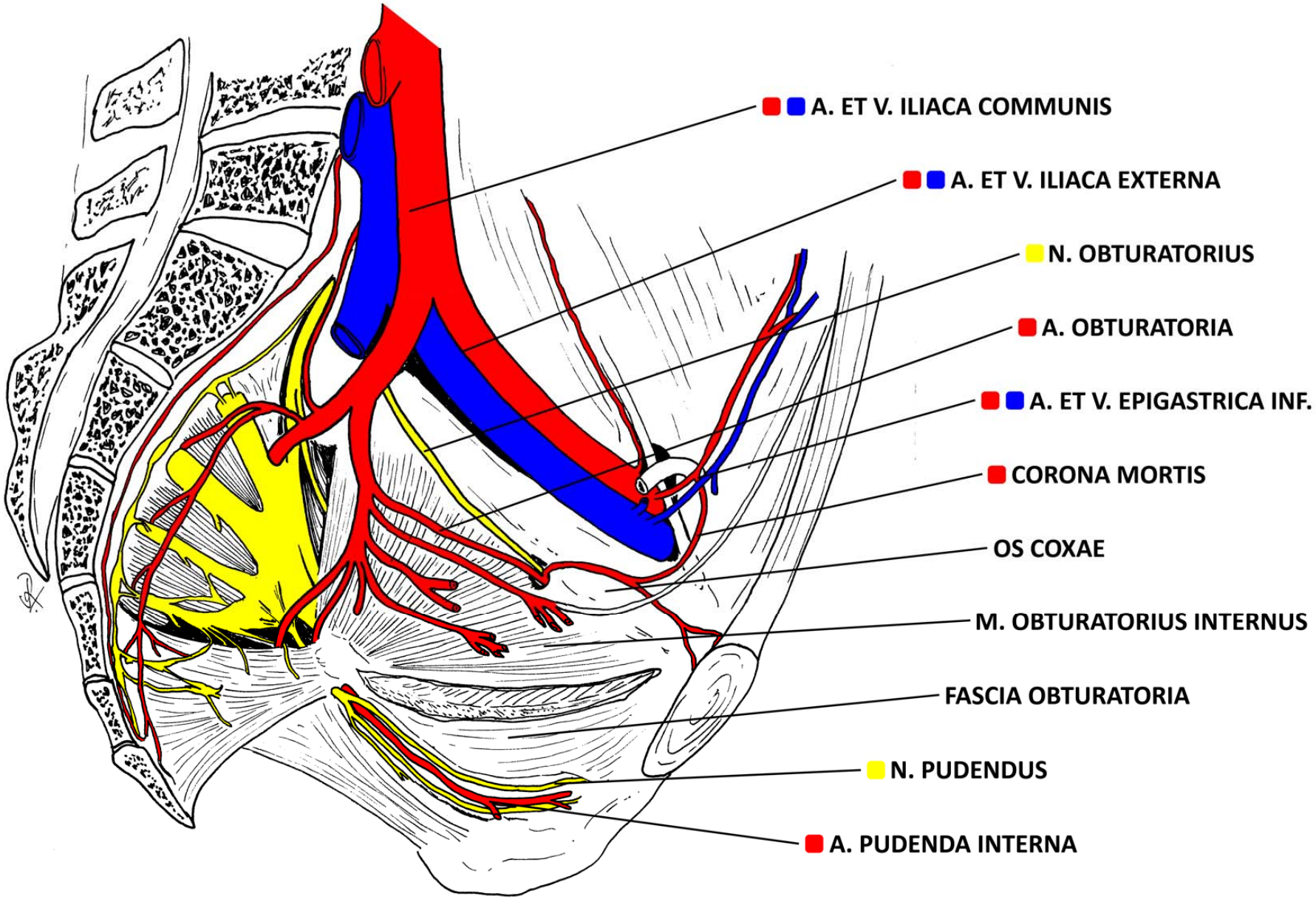
A. ET V. ILIACA COMMUNIS
A. ET V. ILIACA EXTERNA
N. OBTURATORIUS
A. OBTURATORIA
A. ET V. EPIGASTRICA INF.
CORONA MORTIS
OS COXAE
M. OBTURATORIUS INTERNUS
FASCIA OBTURATORIA
N. PUDENDUS
A. PUDENDA INTERNA

TRIGONUM FEMORALE

(Femoral triangle)

/fossa Scarpae major/

BORDERS:

PROXIMAL:
lig. inguinale

MEDIAL:
m. adductor longus

LATERAL:
m. sartorius

CONTENT:

musculus adductor longus (med.)

musculus sartorius (lat.)
nervus obturatorius

arteria et vena obturatoria

nodi lymphoidei inguinales profundi

vena et arteria femoralis + their branches

nervus femoralis + its branches

nervus cutaneus femoris lat.

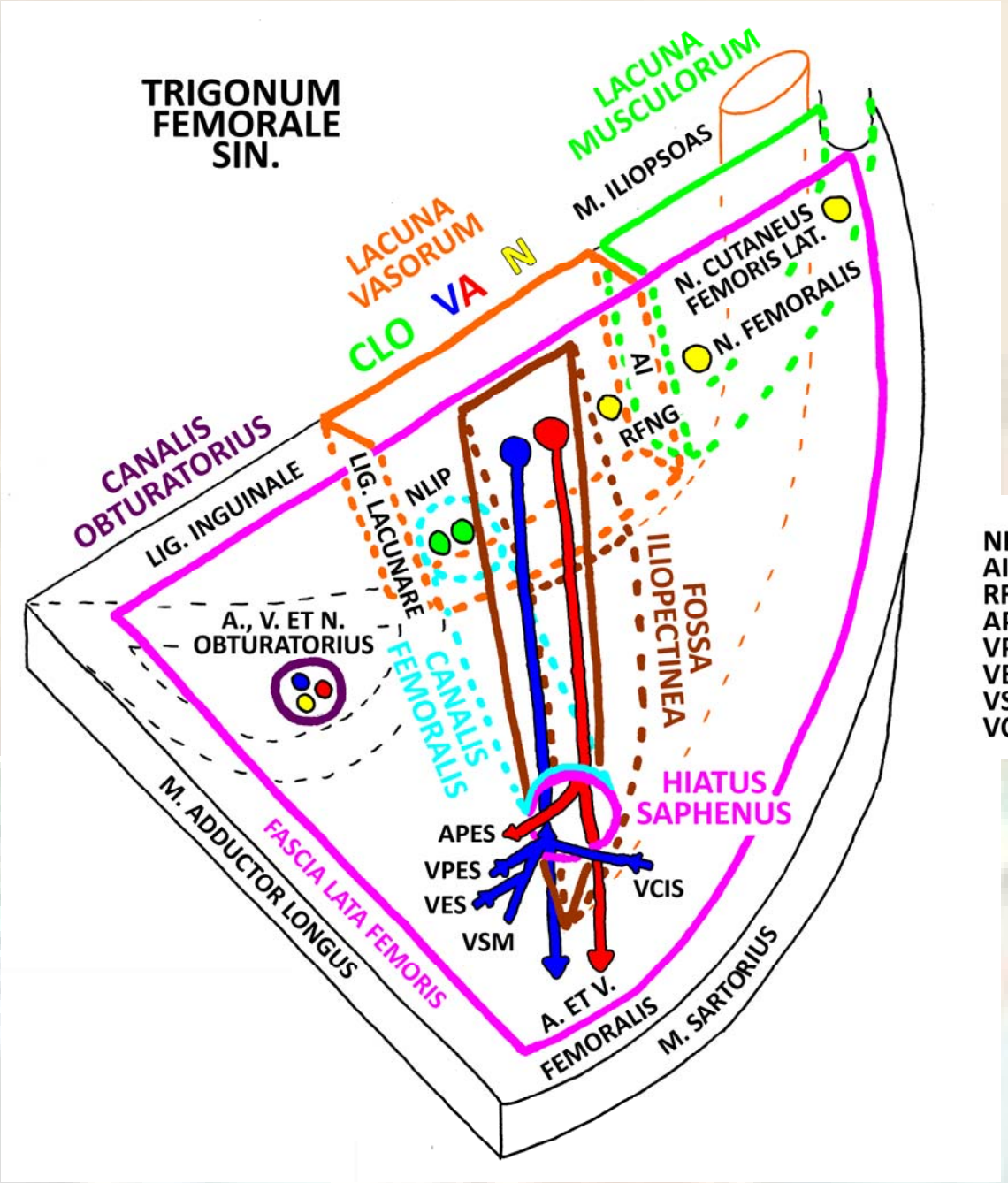

NLIP = NODI LYMPHOIDEI INGUINALES PROFUNDI
AI = ARCUS ILIOPECTINEUS
RFNG = R. FEMORALIS N. GENITOFEMORALIS
APES = A. PUDENDA EXTERNA SUPERFICIALIS
VPES = V. PUDENDA EXTERNA SUPERFICIALIS
VES = V. EPIGASTRICA SUPERFICIALIS
VSM = V. SAPHENA MAGNA
VCIS = V. CIRCUMFLEXA ILIUM SUPERFICIALIS

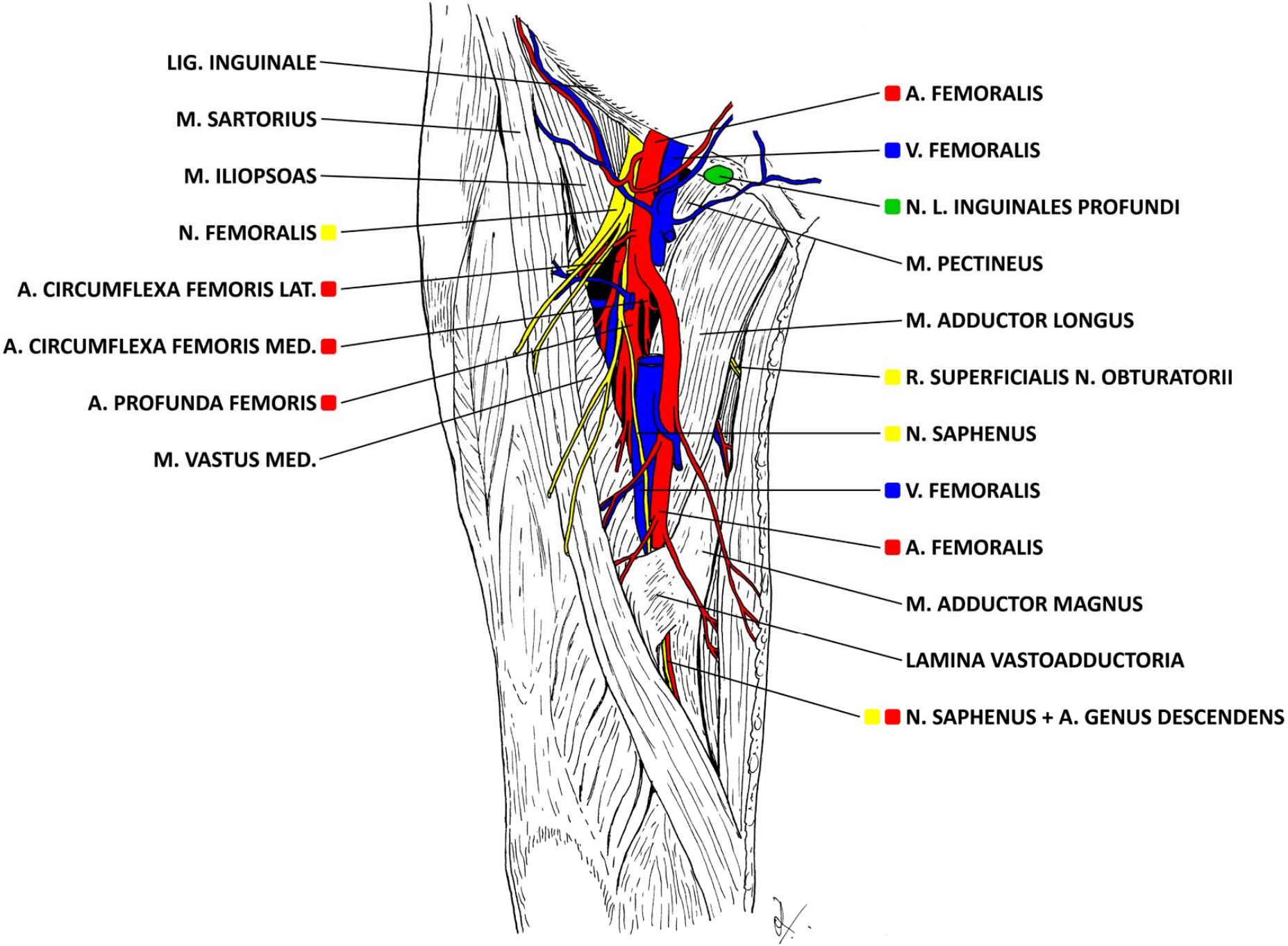
LIG. INGUINALE
M. SARTORIUS
M. ILIOPSOAS
N. FEMORALIS
A. CIRCUMFLEXA FEMORIS LAT.
A. CIRCUMFLEXA FEMORIS MED.
A. PROFUNDA FEMORIS
M. VASTUS MED.
A. FEMORALIS
V. FEMORALIS
N. L. INGUINALES PROFUNDI
M. PECTINEUS
M. ADDUCTOR LONGUS
R. SUPERFICIALIS N. OBTURATORII
N. SAPHENUS
V. FEMORALIS
A. FEMORALIS
M. ADDUCTOR MAGNUS
LAMINA VASTOADDUCTORIA
N. SAPHENUS + A. GENUS DESCENDENS

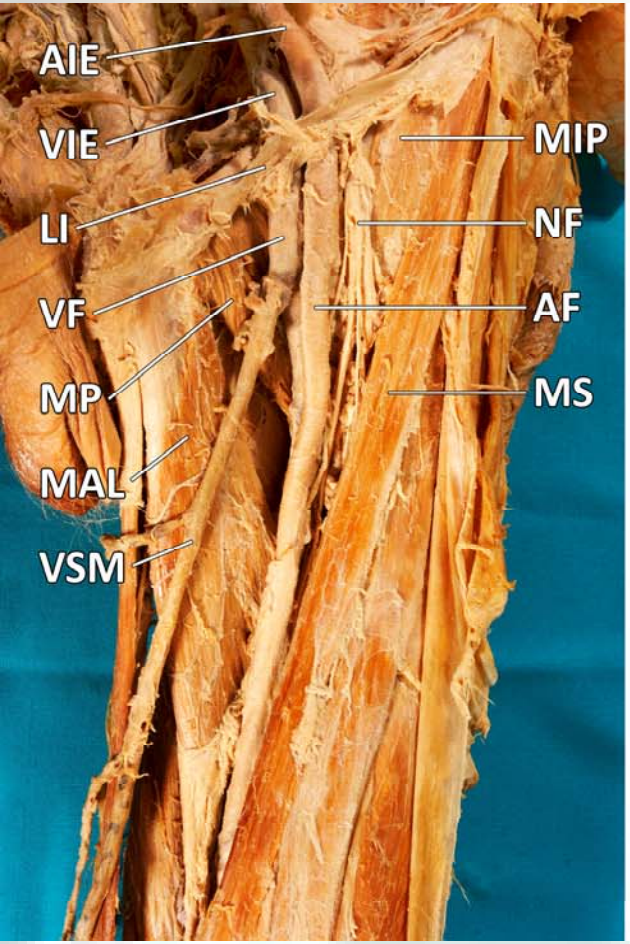

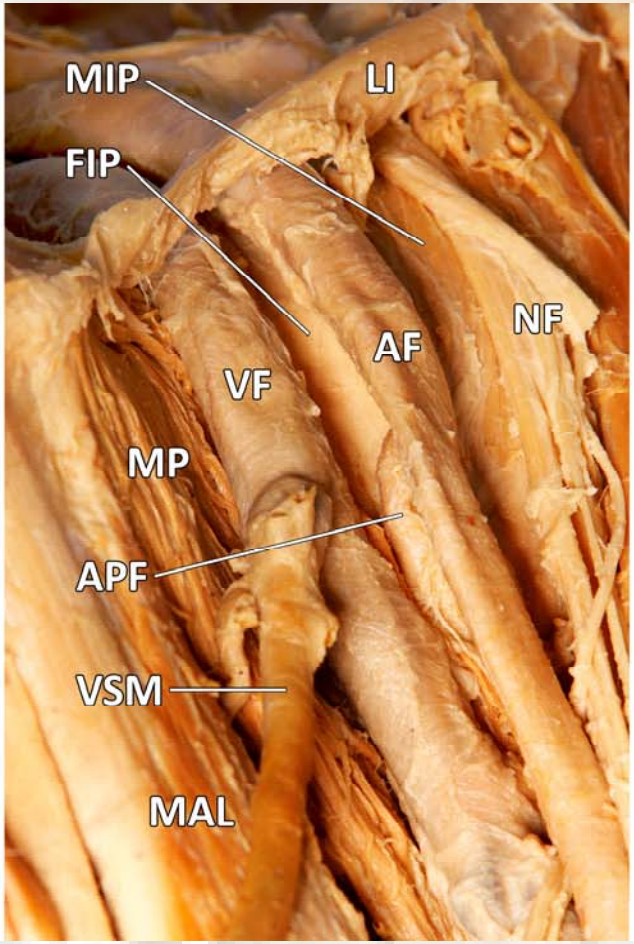

AIE - A. ILIACA EXTERNA
VIE - V. ILIACA EXTERNA
LI - LIG. INGUINALE
VF - V. FEMORALIS
MP - M. PECTINEUS
MAL - M. ADDUCTOR LONGUS
VSM - V. SAPHENA MAGNA
MIP - M. ILIOPSOAS
NF - N. FEMORALIS
AF - A. FEMORALIS
MS - M. SARTORIUS

FIP - FASCIA ILIOPECTINEA
APF - A. PROFUNDA FEMORIS

FOSSA ILIOPECTINEA

/fossa Scarpae minor/

at the bottom of the femoral triangle

BORDERS:

LATERAL:

m. iliopsoas

MEDIAL:

m. pectineus

BOTTOM-DORSALY:

fascia iliopectinea

CONTENT:

vena femoralis

arteria femoralis

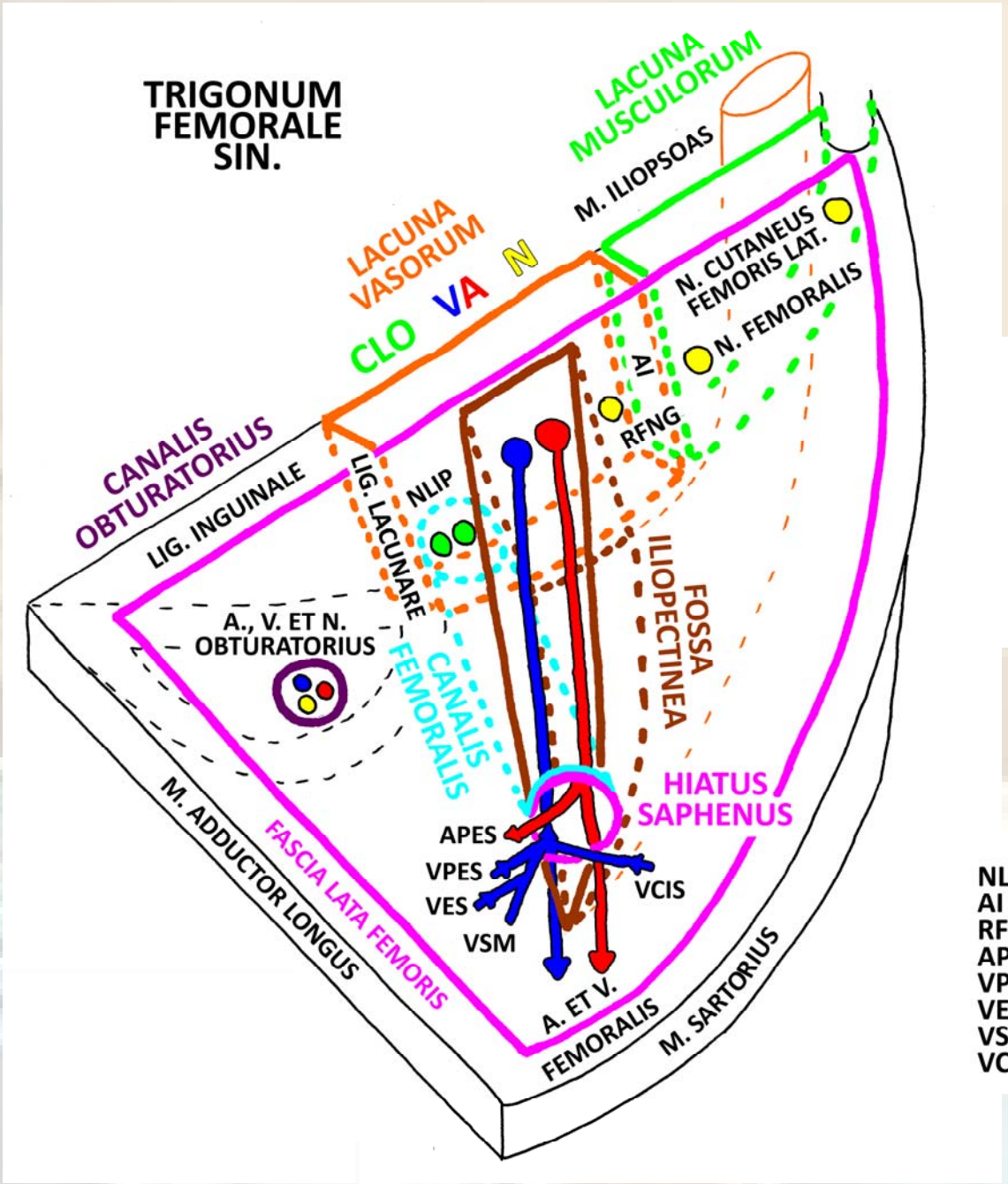

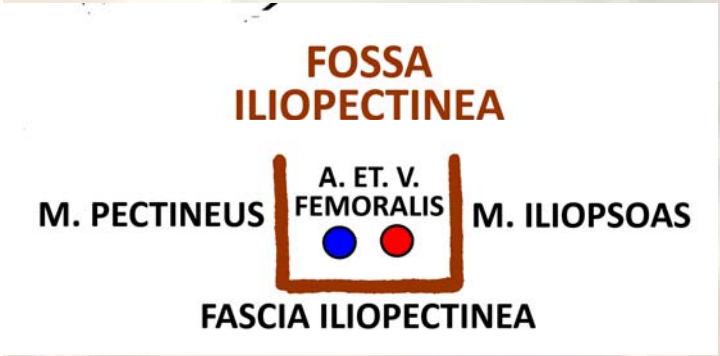

NLIP = NODI LYMPHOIDEI INGUINALES PROFUNDI
AI = ARCUS ILIOPECTINEUS
RFNG = R. FEMORALIS N. GENITOFEMORALIS
APES = A. PUDENDA EXTERNA SUPERFICIALIS
VPES = V. PUDENDA EXTERNA SUPERFICIALIS
VES = V. EPIGASTRICA SUPERFICIALIS
VSM = V. SAPHENA MAGNA
VCIS = V. CIRCUMFLEXA ILIUM SUPERFICIALIS

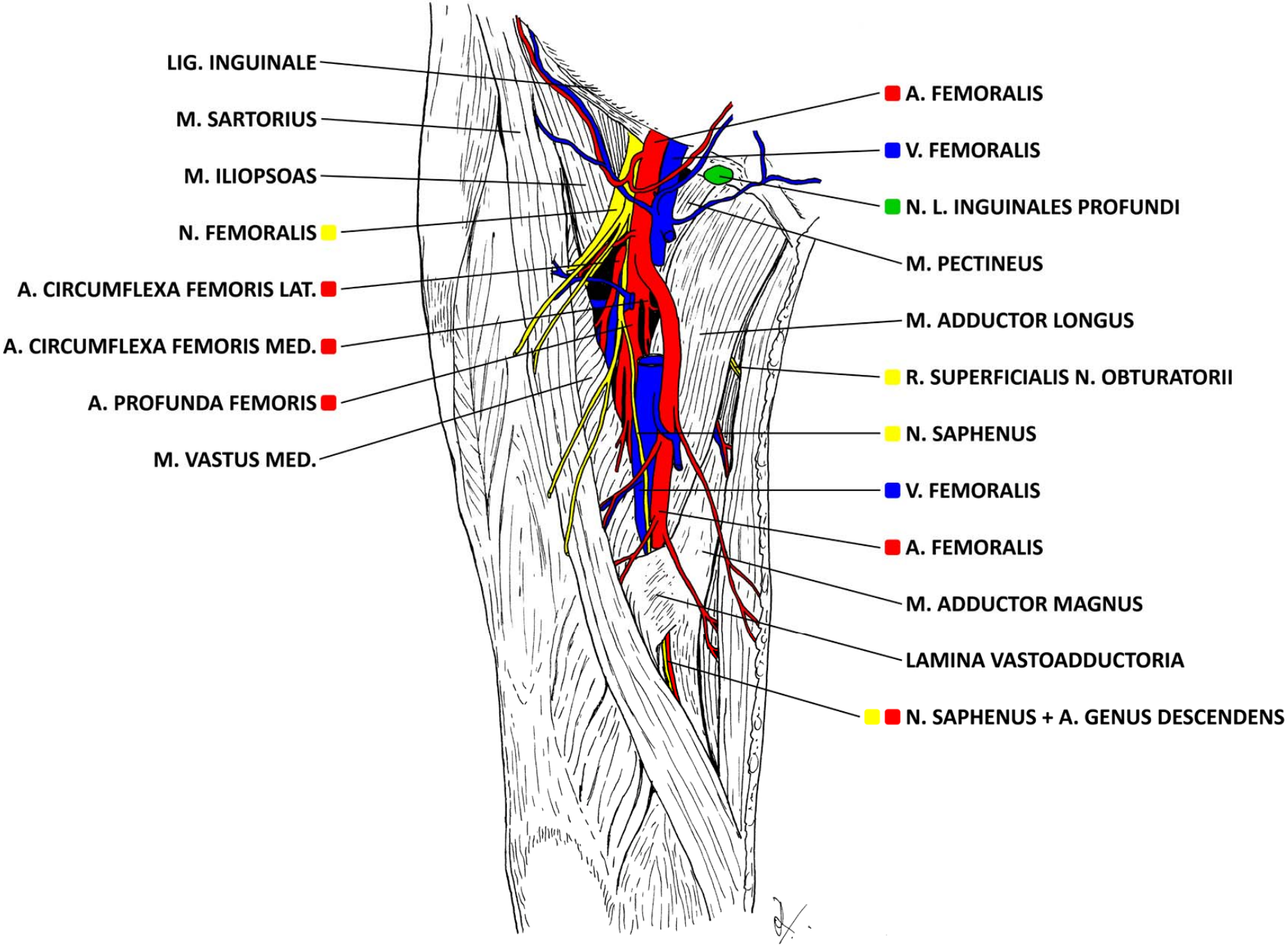
LIG. INGUINALE
M. SARTORIUS
M. ILIOPSOAS
N. FEMORALIS
A. CIRCUMFLEXA FEMORIS LAT.
A. CIRCUMFLEXA FEMORIS MED.
A. PROFUNDA FEMORIS
M. VASTUS MED.
A. FEMORALIS
V. FEMORALIS
N. L. INGUINALES PROFUNDI
M. PECTINEUS
M. ADDUCTOR LONGUS
R. SUPERFICIALIS N. OBTURATORII
N. SAPHENUS
V. FEMORALIS
A. FEMORALIS
M. ADDUCTOR MAGNUS
LAMINA VASTOADDUCTORIA
N. SAPHENUS + A. GENUS DESCENDENS

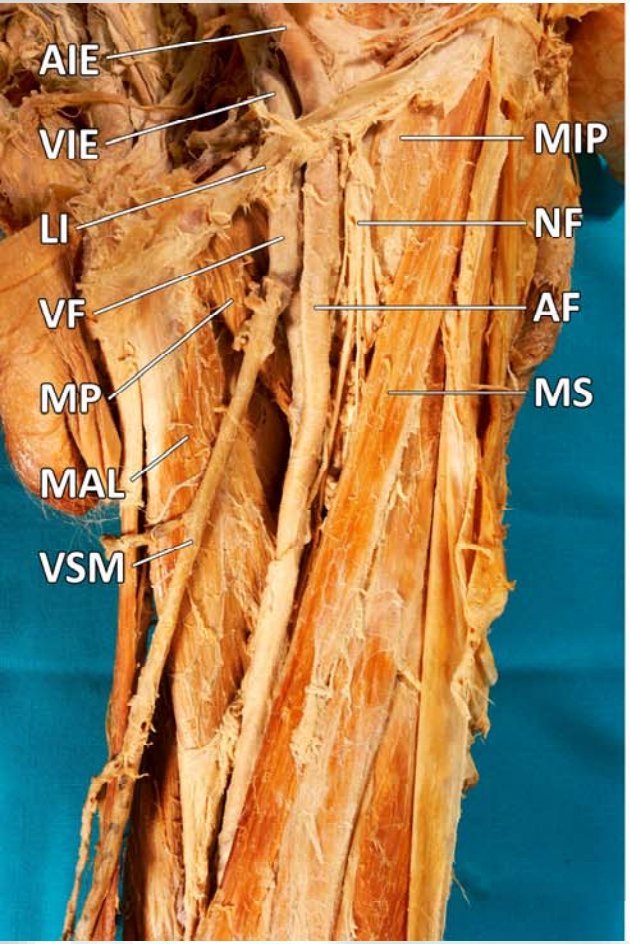

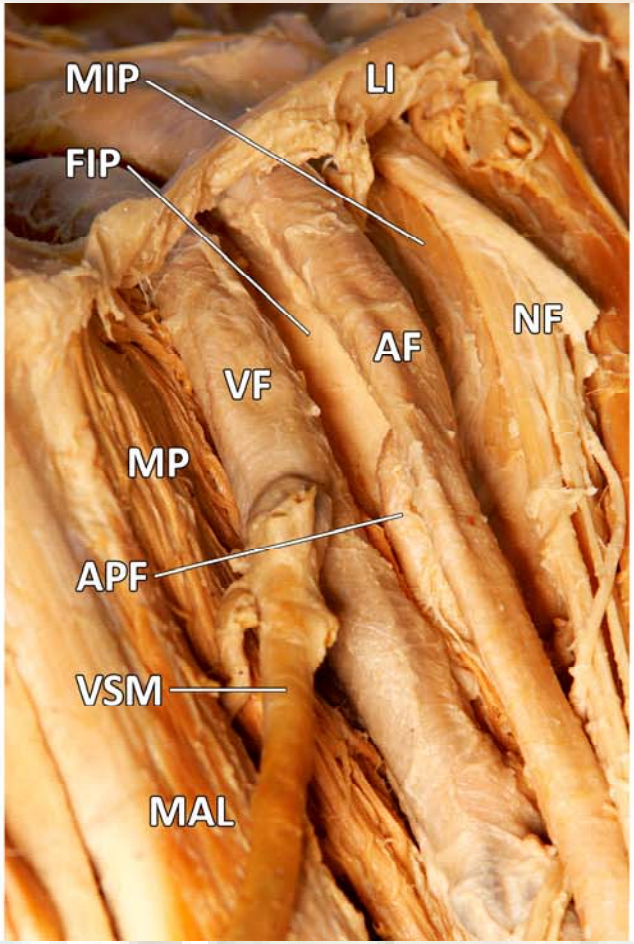

AIE - A. ILIACA EXTERNA
VIE - V. ILIACA EXTERNA
LI - LIG. INGUINALE
VF - V. FEMORALIS
MP - M. PECTINEUS
MAL - M. ADDUCTOR LONGUS
VSM - V. SAPHENA MAGNA
MIP - M. ILIOPSOAS
NF - N. FEMORALIS
AF - A. FEMORALIS
MS - M. SARTORIUS

FIP - FASCIA ILIOPECTINEA
APF - A. PROFUNDA FEMORIS

HIATUS SAPHENUS

(Saphenous opening)

BORDERS:

passage to fossa liopectinea through

fascia cribrosa

(part of fascia lata femoris)

margo falciformis (lat.)

CONTENT:

vena epigastrica supf. (prox.)

arteria pudenda externa supf.

venae pudendae ext. (med.)

vena circumflexa ilium supf. (lat.)

vena saphena magna (dist.)

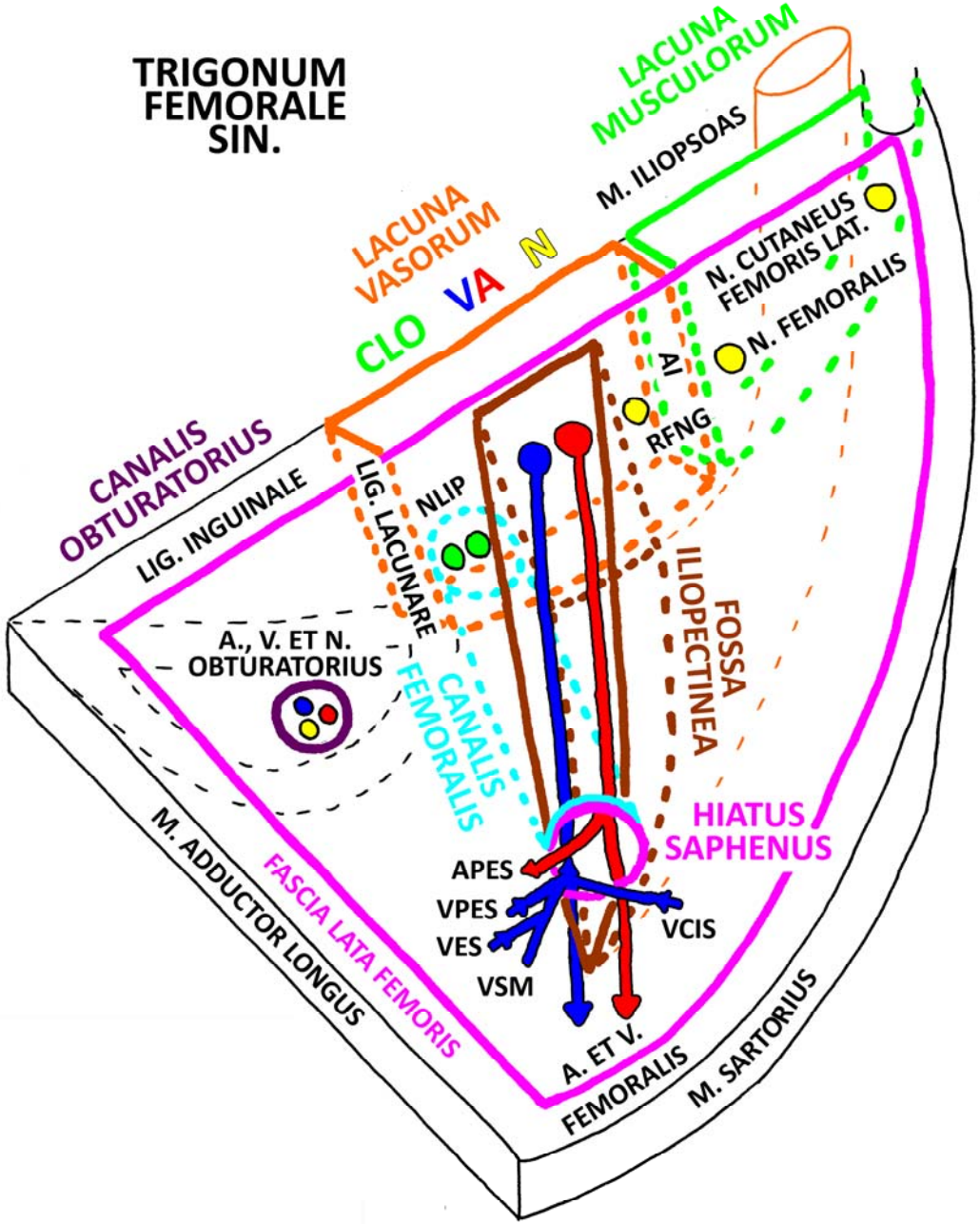

NLIP = NODI LYMPHOIDEI INGUINALES PROFUNDI
AI = ARCUS ILIOPECTINEUS
RFNG = R. FEMORALIS N. GENITOFEMORALIS
APES = A. PUDENDA EXTERNA SUPERFICIALIS
VPES = V. PUDENDA EXTERNA SUPERFICIALIS
VES = V. EPIGASTRICA SUPERFICIALIS
VSM = V. SAPHENA MAGNA
VCIS = V. CIRCUMFLEXA ILIUM SUPERFICIALIS

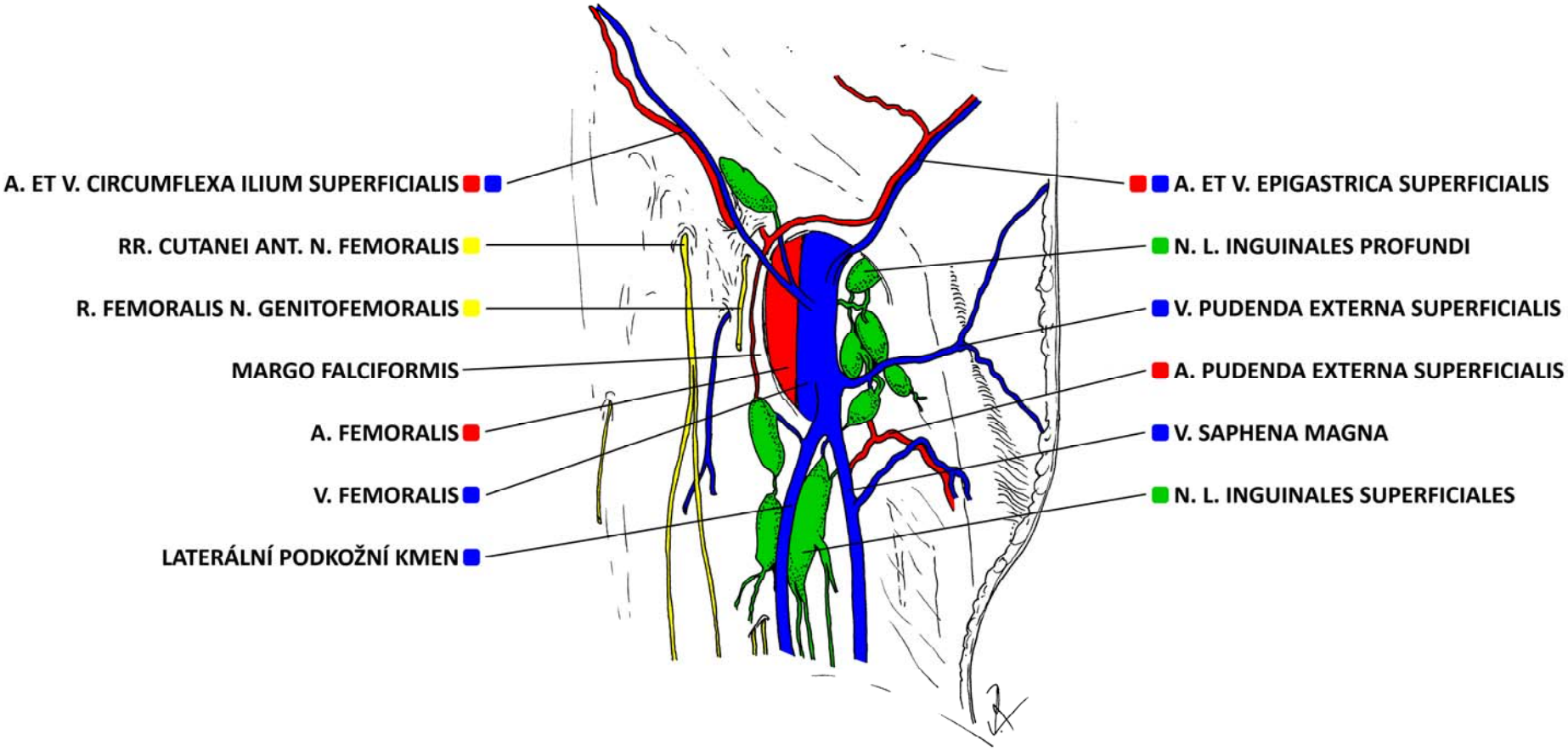
A. ET V. CIRCUMFLEXA ILIUM SUPERFICIALIS
RR. CUTANEI ANT. N. FEMORALIS
R. FEMORALIS N. GENITOFEMORALIS
MARGO FALCIFORMIS
A. FEMORALIS
V. FEMORALIS
LATERÁLNÍ PODKOŽNÍ KMEN
A. ET V. EPIGASTRICA SUPERFICIALIS
N. L. INGUINALES PROFUNDI
V. PUDENDA EXTERNA SUPERFICIALIS
A. PUDENDA EXTERNA SUPERFICIALIS
V. SAPHENA MAGNA
N. L. INGUINALES SUPERFICIALES

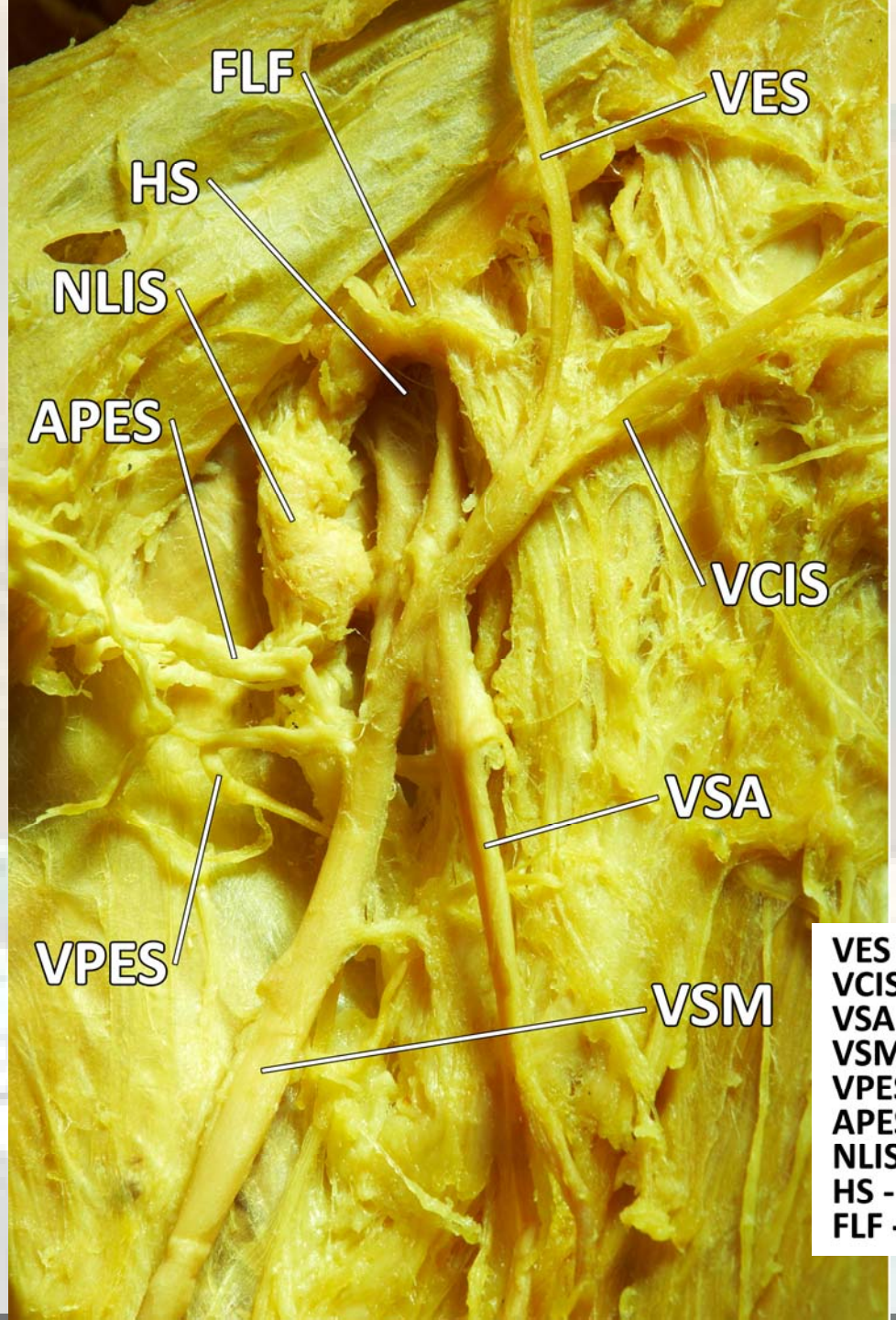

VES - V. EPIGASTRICA SUPERFICIALIS
VCIS - V. CIRCUMFLEXA ILIUM SUPERFICIALIS
VSA - V. SAPHENA ACCESSORIA
VSM - V. SAPHENA MAGNA
VPES - V. PUDENDA EXTERNA SUPERFICIALIS
APES - A. PUDENDA EXTERNA SUPERFICIALIS
NLIS - NODI LYMPHOIDEI INGUINALES SUPERFICIALES
HS - HIATUS SAPHENUS
FLF - FASCIA LATA FEMORIS

CANALIS ADDUCTORIUS

/Hunter´s canal/

BORDERS:

MEDIAL:

m. adductor longus

LATERAL:

m. vastus medialis

VENTRAL:

lamina vastoadductoria

DORSAL:

m. adductor magnus

canal is covered by m. sartorius

CONTENT:

vena femoralis

arteria femoralis

nervus saphenus */pierces lamina vastoadductoria together with branch of a. genus descendens/*

CANALIS ADDUCTORIUS DX.

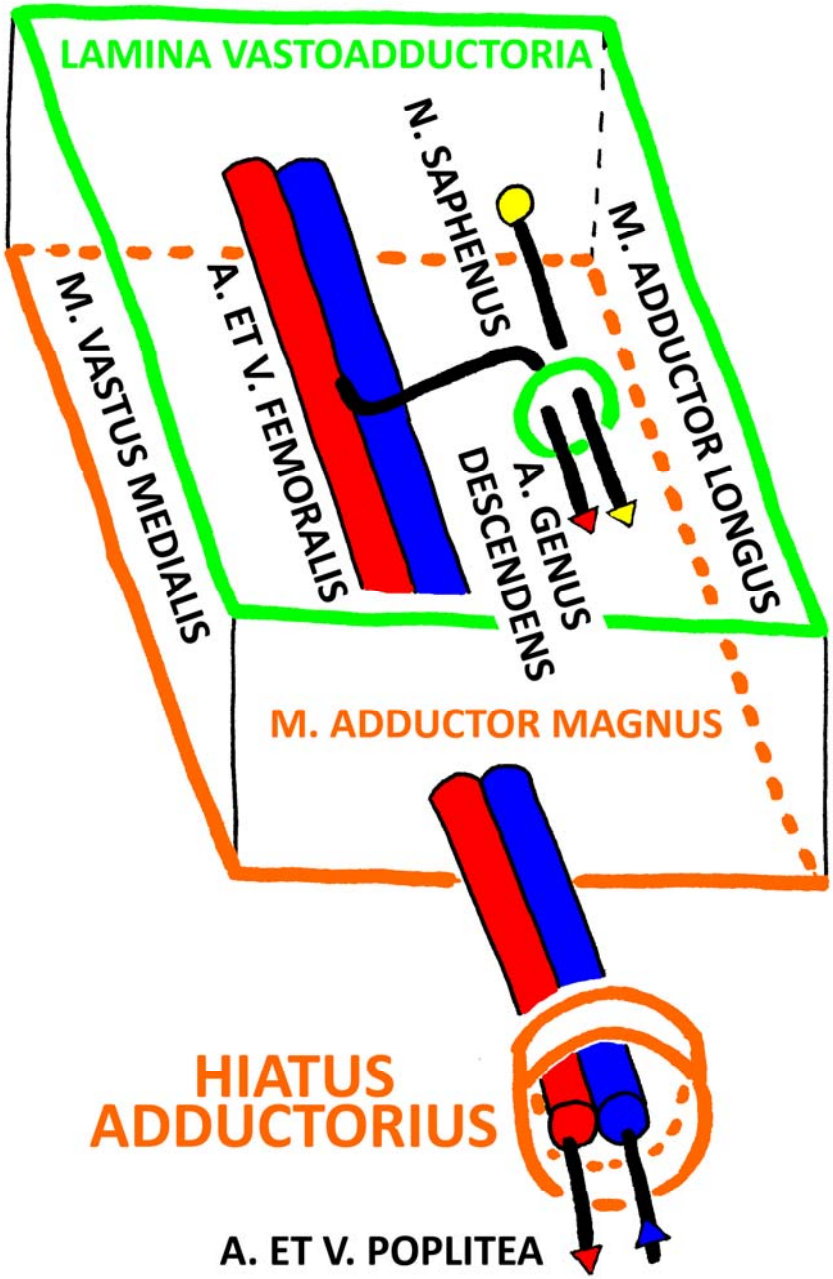

HIATUS ADDUCTORIUS

BORDERS:

distal end of adductor canal between two insertion tendons of m.adductor magnus

CONTENT:

arteria femoralis

vena femoralis

changed in

arteria poplitea

vena poplitea

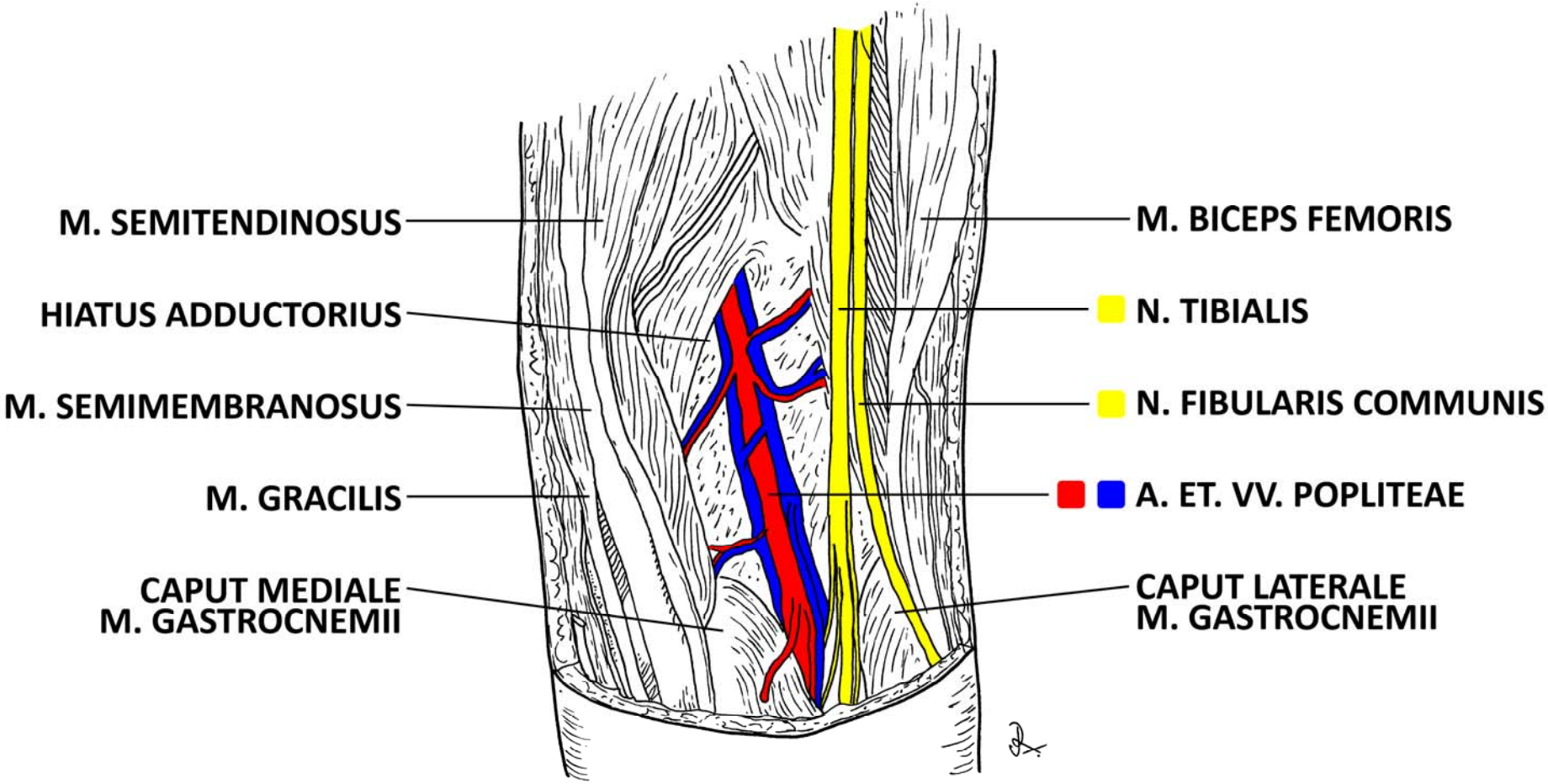
M. SEMITENDINOSUS
HIATUS ADDUCTORIUS
M. SEMIMEMBRANOSUS
M. GRACILIS
CAPUT MEDIALE
M. GASTROCNEMII
M. BICEPS FEMORIS
N. TIBIALIS
N. FIBULARIS COMMUNIS
A. ET. VV. POPLITEAE
CAPUT LATERALE
M. GASTROCNEMII

FOSSA POPLITEA

(Popliteal fossa)

BORDERS:

MEDIAL AND PROXIMAL:
m. semimembranosus
m.semitendinosus

LATERAL AND PROXIMAL:
m. biceps femoris

DISTAL:
caput mediale et laterale m. gastrocnemii

BOTTOM-DORSAL:
m. popliteus

CONTENT:

nervus ischiadicus
divides into
nervus tibialis and nervus fibularis communis

vena poplitea + its tributaries

arteria poplitea + its branches

nodi lymphoidei popliteales profundi

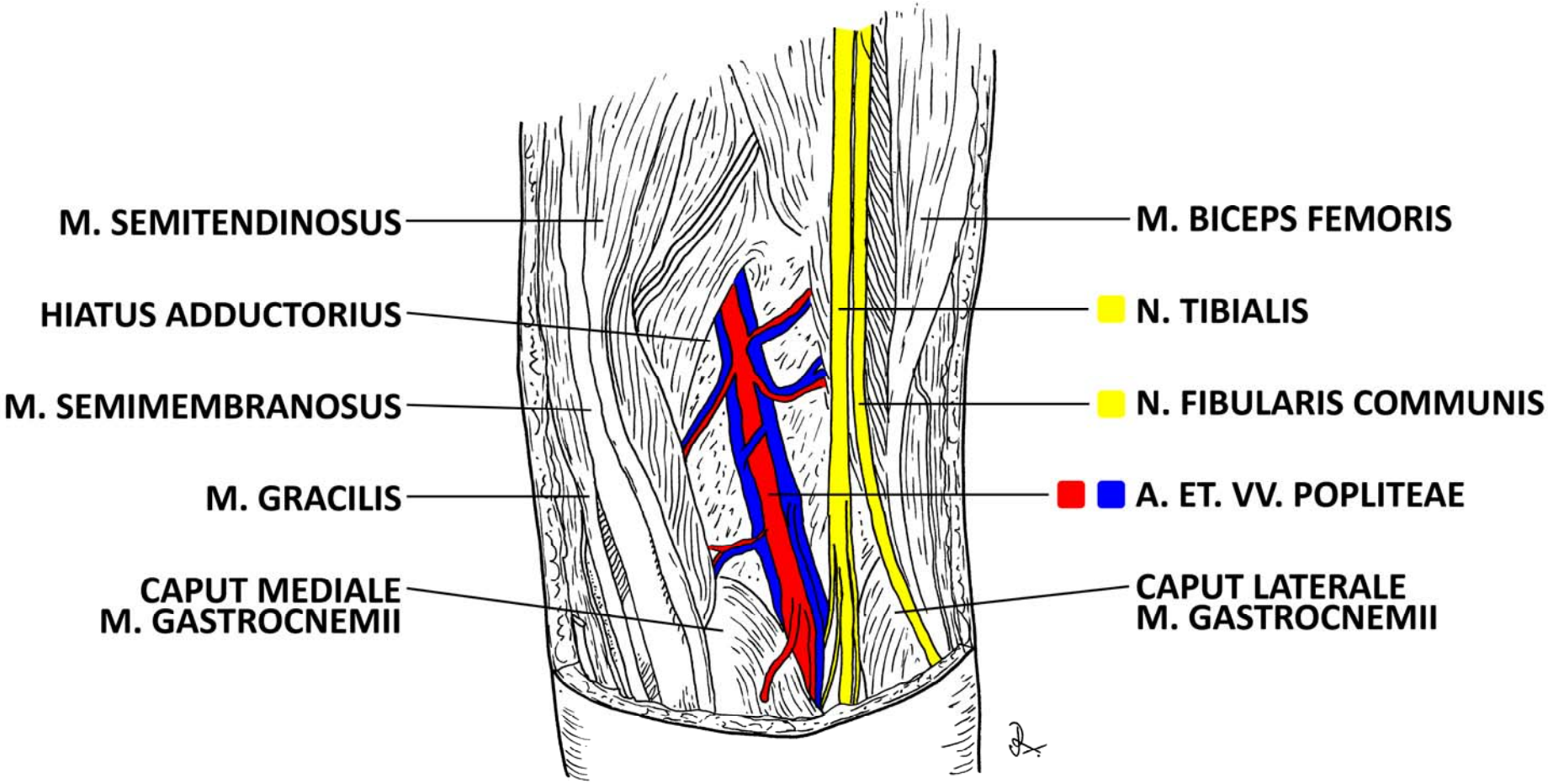
M. SEMITENDINOSUS
HIATUS ADDUCTORIUS
M. SEMIMEMBRANOSUS
M. GRACILIS
CAPUT MEDIALE
M. GASTROCNEMII
M. BICEPS FEMORIS
N. TIBIALIS
N. FIBULARIS COMMUNIS
A. ET. VV. POPLITEAE
CAPUT LATERALE
M. GASTROCNEMII

FOSSA POPLITEA DX.

A VE N

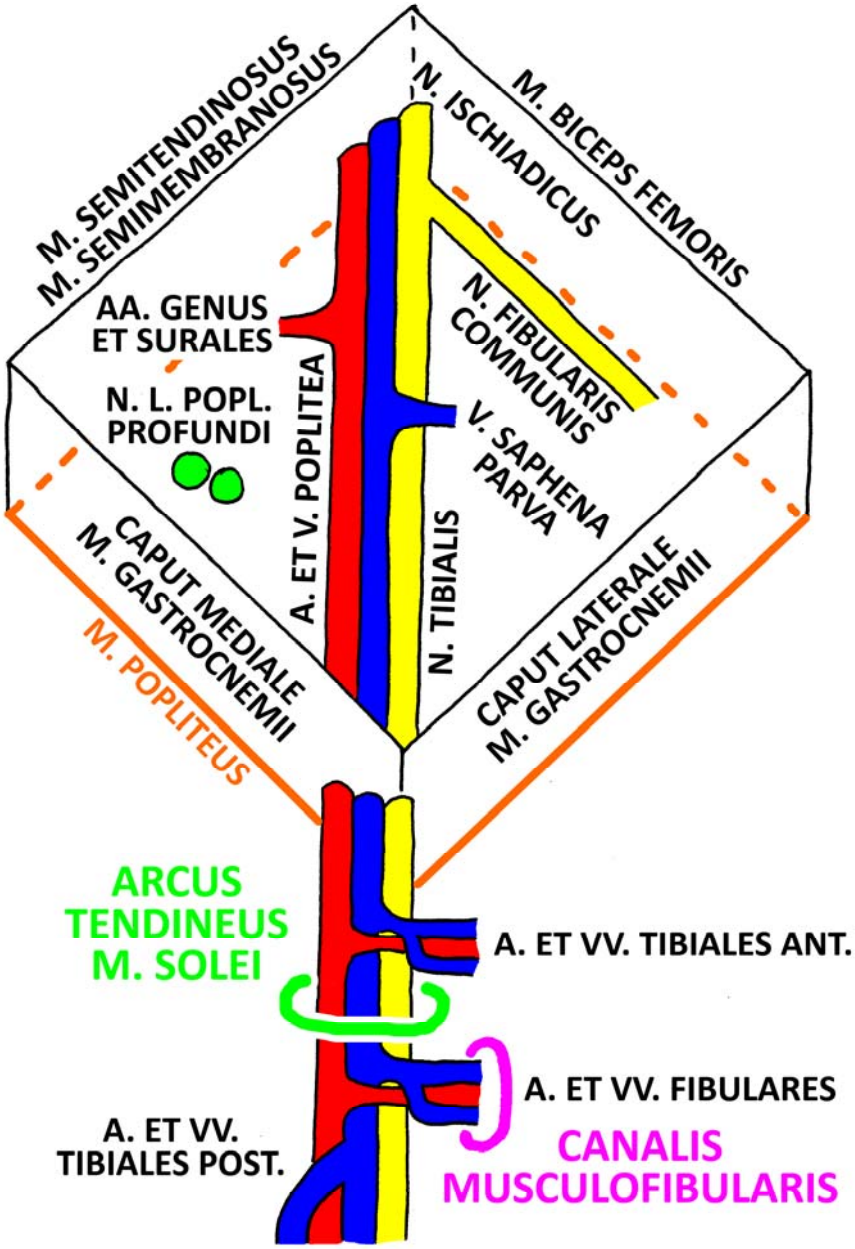

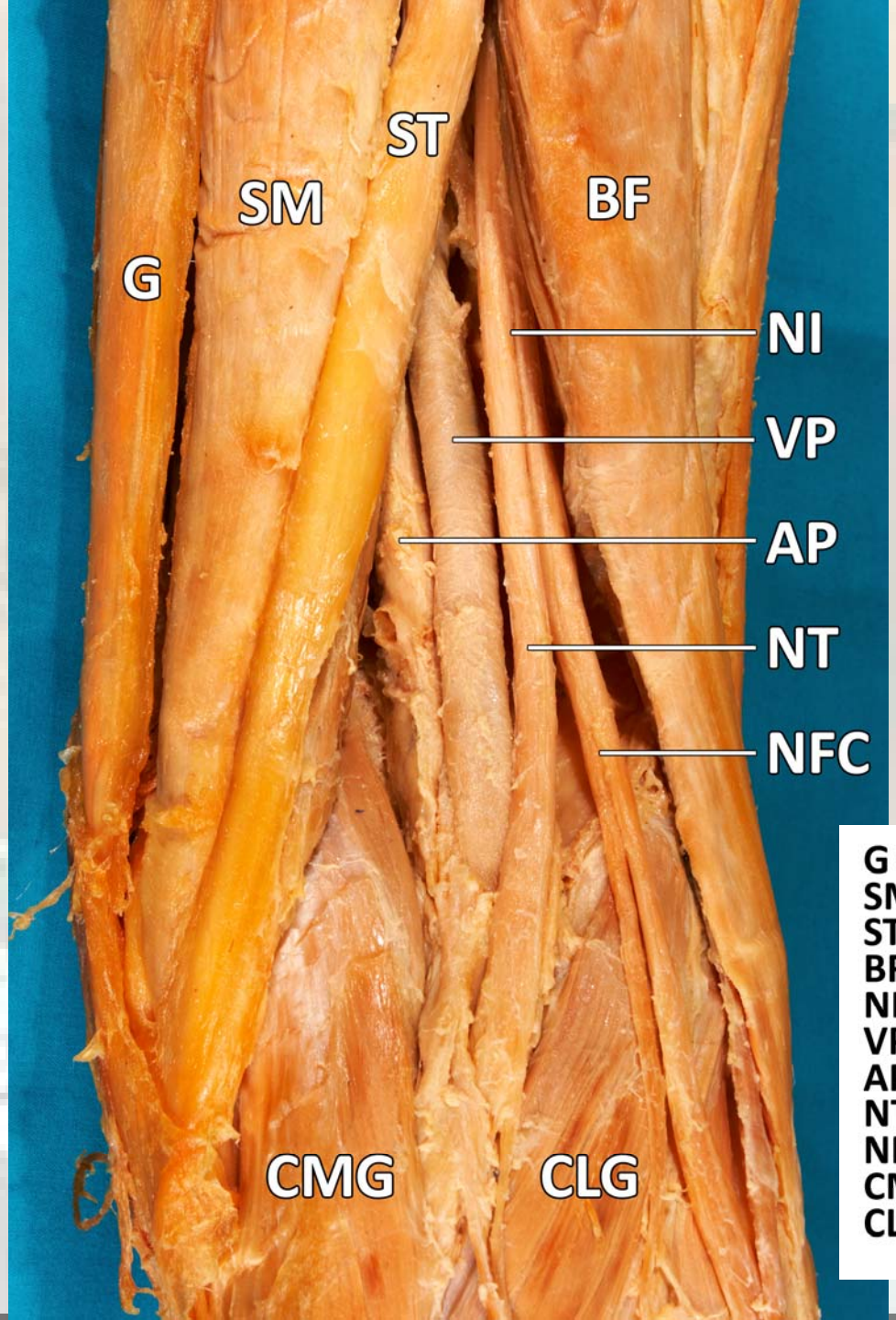

G - M. GRACILIS
SM - M. SEMIMEMBRANOSUS
ST - M. SEMITENDINOSUS
BF - M. BICEPS FEMORIS
NI - N. ISCHIADICUS
VP - V. POPLITEA
AP - A. POPLITEA
NT - N. TIBIALIS
NFC - N. FIBULARIS COMMUNIS
CMG - CAPUT MEDIALE M. GASTROCNEMII
CLG - CAPUT LATERALE M. GASTROCNEMII

ARCUS TENDINEUS M. SOLEI

(tendinous arch of soleus muscle)

BORDERS:

tendinous arch in the origin of m. soleus stretchted from fibula to the posterior surface of tibia above the membrana interossea cruris

CONTENT:

nervus tibialis

arteria tibialis post.

vena tibialis post.

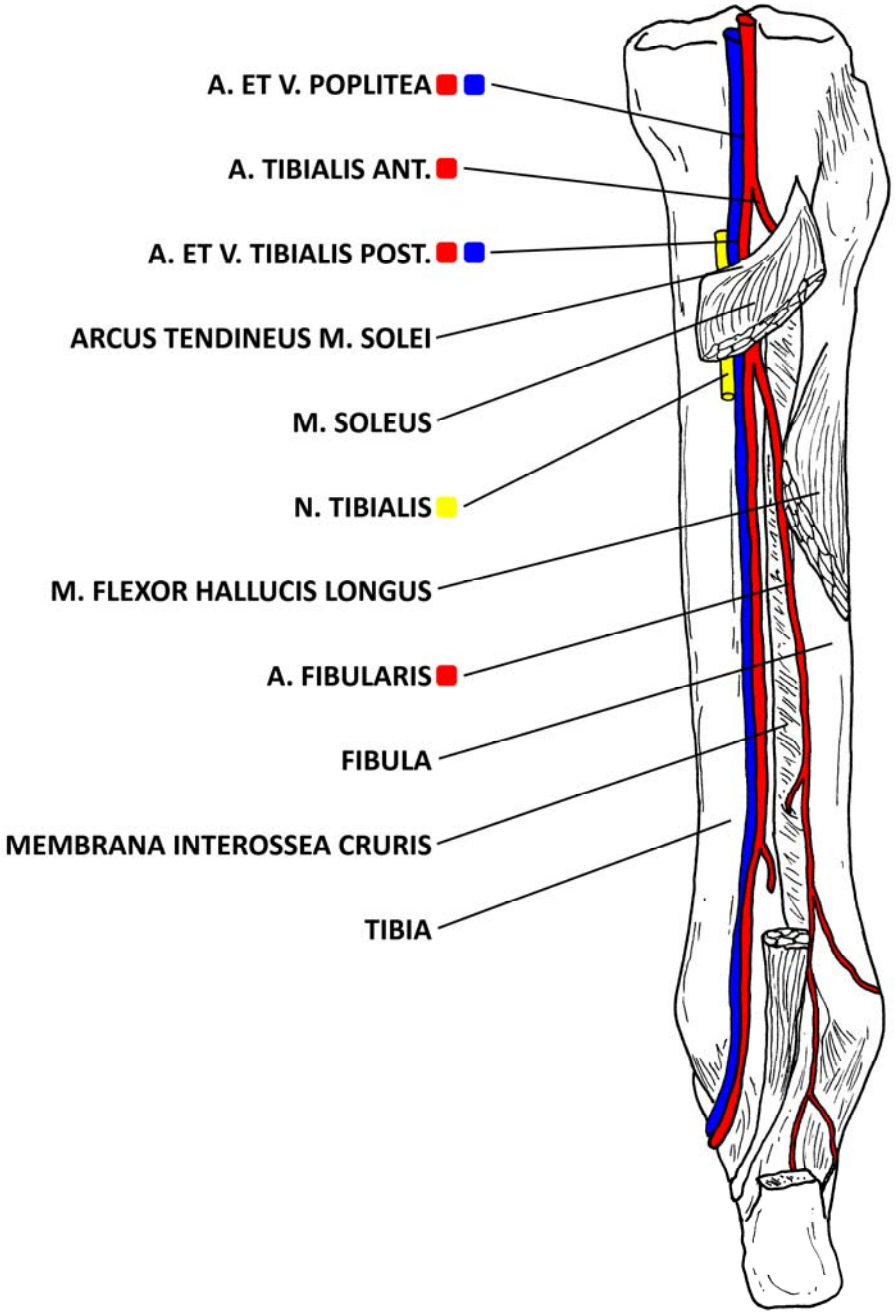
A. ET V. POPLITEA
A. TIBIALIS ANT.
A. ET V. TIBIALIS POST.
ARCUS TENDINEUS M. SOLEI
M. SOLEUS
N. TIBIALIS
M. FLEXOR HALLUCIS LONGUS
A. FIBULARIS
FIBULA
MEMBRANA INTEROSSEA CRURIS
TIBIA

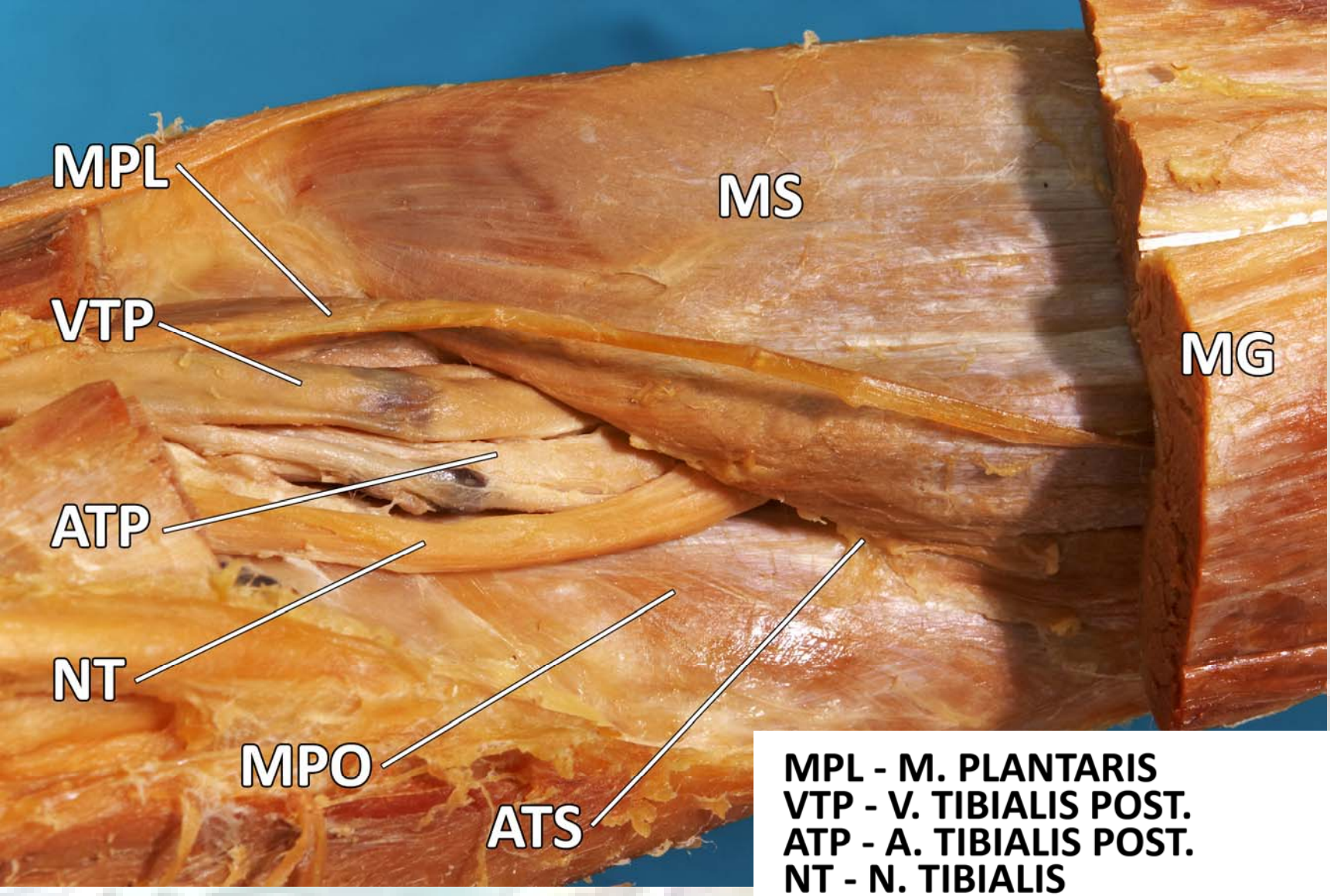

MPL - M. PLANTARIS
VTP - V. TIBIALIS POST.
ATP - A. TIBIALIS POST.
NT - N. TIBIALIS
MPO - M. POPLITEUS
ATS - ARCUS TENDINEUS M. SOLEI
MS - M. SOLEUS
MG - M. GASTROCNEMIUS

CANALIS MUSCULOFIBULARIS

/Hyrtl´s canal/

BORDERS:

LATERAL:

fibula

MEDIALLY:

m. flexor hallucis longus

CONTENT:

vena fibularis

arteria fibularis

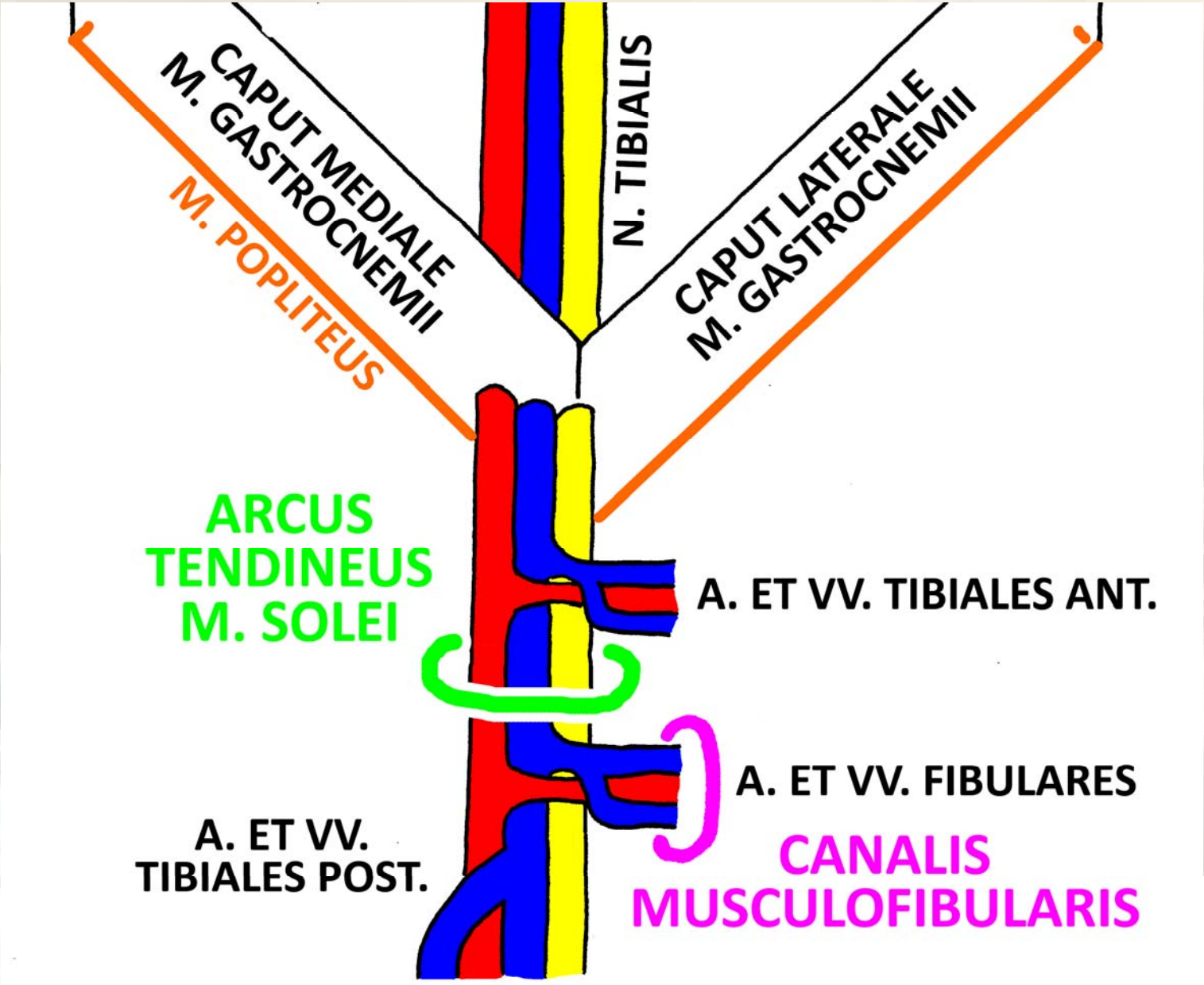
CAPUT MEDIALE
M. GASTROCNEMII
N. TIBIALIS
CAPUT LATERALE
M. GASTROCNEMII
M. POPLITEUS
ARCUS
TENDINEUS
M. SOLEI
A. ET VV. TIBIALES ANT.
A. ET VV. FIBULARES
A. ET VV.
TIBIALES POST.
CANALIS
MUSCULOFIBULARIS

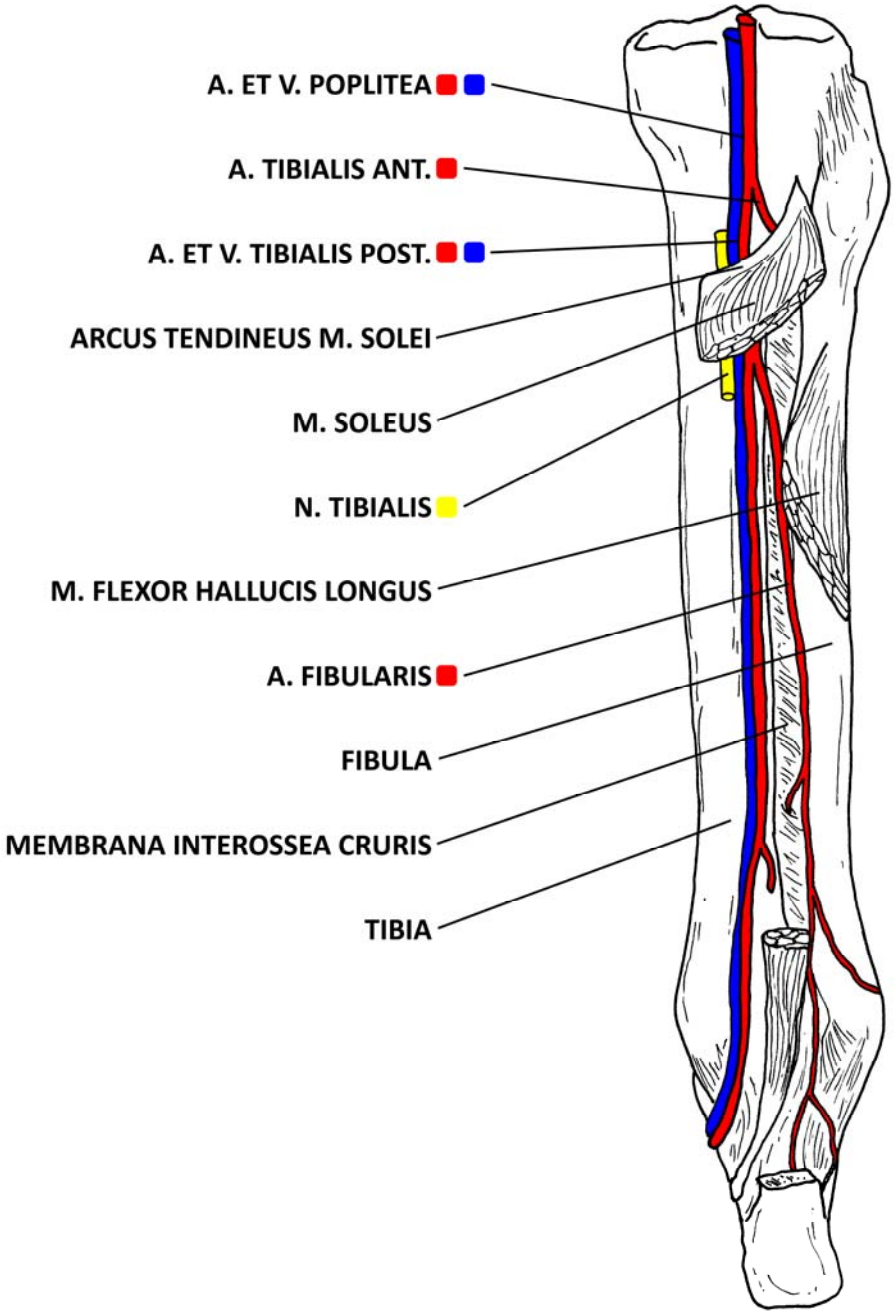
A. ET V. POPLITEA
A. TIBIALIS ANT.
A. ET V. TIBIALIS POST.
ARCUS TENDINEUS M. SOLEI
M. SOLEUS
N. TIBIALIS
M. FLEXOR HALLUCIS LONGUS
A. FIBULARIS
FIBULA
MEMBRANA INTEROSSEA CRURIS
TIBIA

STRUCTURES BEHIND THE MEDIAL MALLEOLUS

(Tarsal canal)

BORDERS:

MEDIAL:
retinaculum musculorum flexorum

VENTRAL:
malleolus medialis

DORSAL:
tuber calcanei

CONTENT:

malleolus medialis (ventr.)

tuber calcanei (dors.) - tendo m. tibialis post.

tendo m. flexoris digitorum longi

arteria vena tibialis post.
vena tibialis post.
n. tibialis

tendo m. flexoris hallucis longi
/the only tendon not leaning against the malleolus/

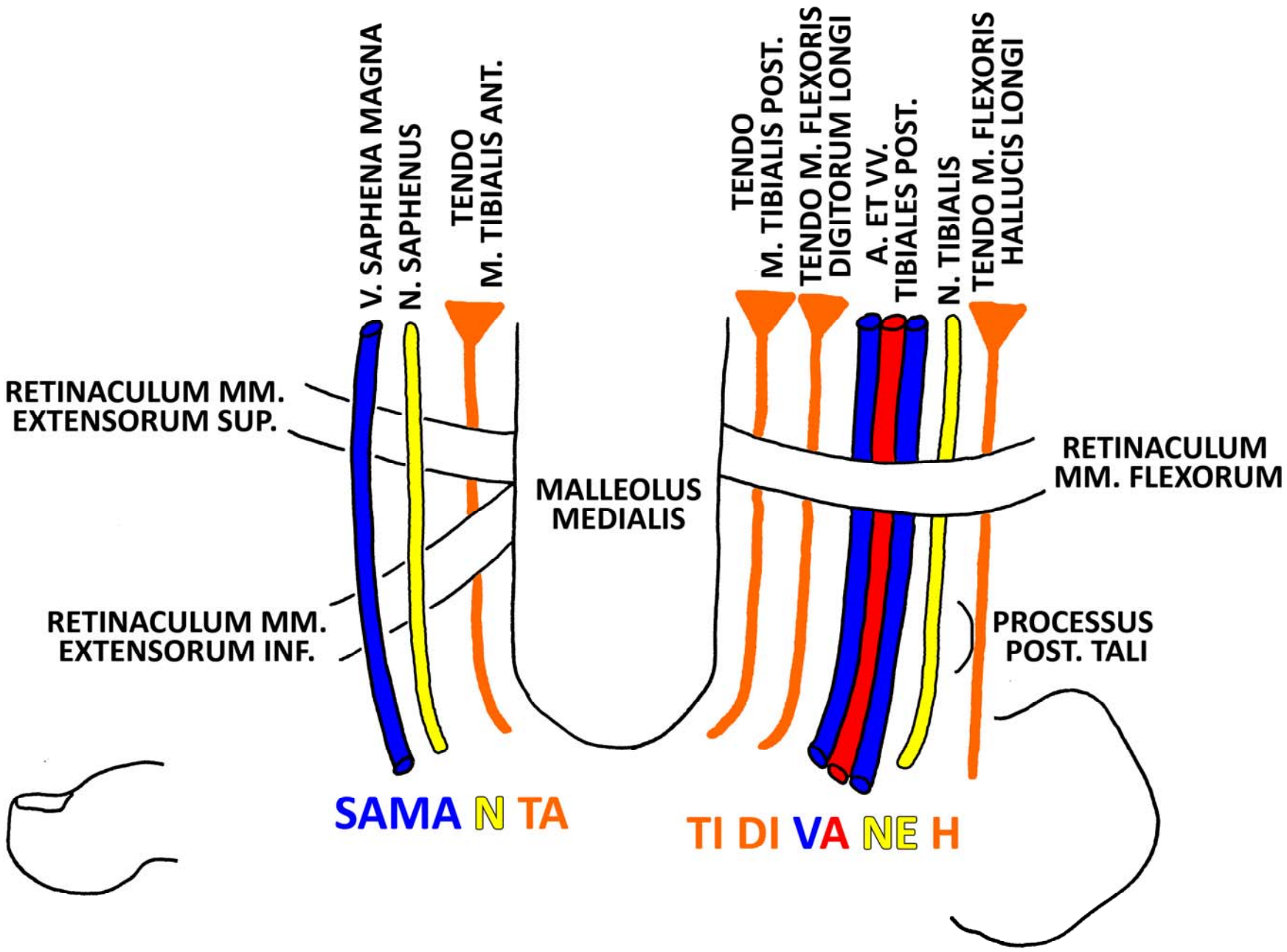
V. SAPHENA MAGNA
N. SAPHENUS
TENDO
M. TIBIALIS ANT.
TENDO
M. TIBIALIS POST.
TENDO M. FLEXORIS
DIGITORUM LONGI
A. ET VV.
TIBIALES POST.
N. TIBIALIS
TENDO M. FLEXORIS
HALLUCIS LONGI
RETINACULUM MM.
EXTENSORUM SUP.
MALLEOLUS
MEDIALIS
RETINACULUM
MM. FLEXORUM
RETINACULUM MM.
EXTENSORUM INF.
PROCESSUS
POST. TALI
SAMA N TA
TI DI VA NE H

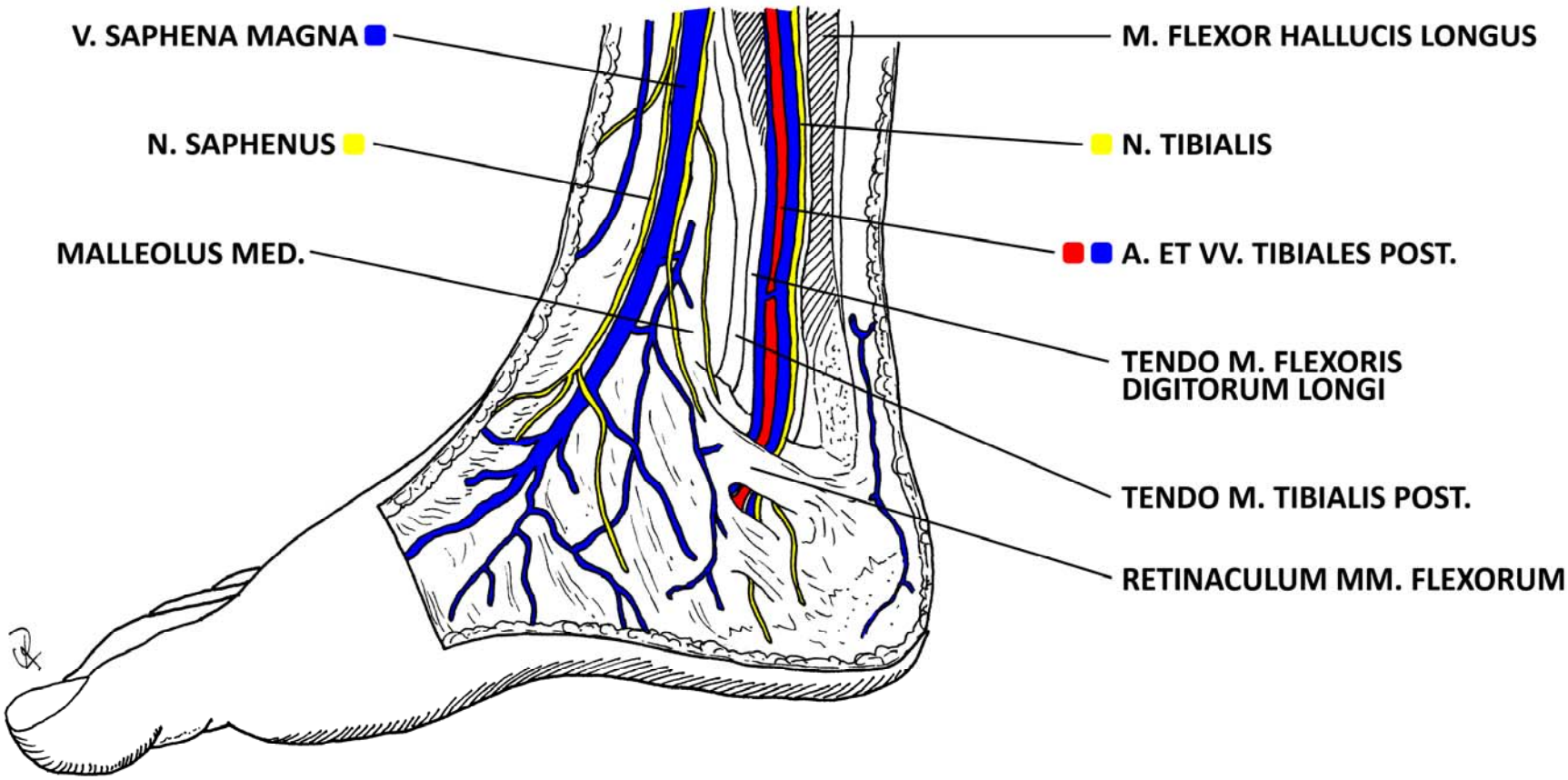
V. SAPHENA MAGNA
N. SAPHENUS
MALLEOLUS MED.
M. FLEXOR HALLUCIS LONGUS
N. TIBIALIS
A. ET VV. TIBIALES POST.
TENDO M. FLEXORIS DIGITORUM LONGI
TENDO M. TIBIALIS POST.
RETINACULUM MM. FLEXORUM

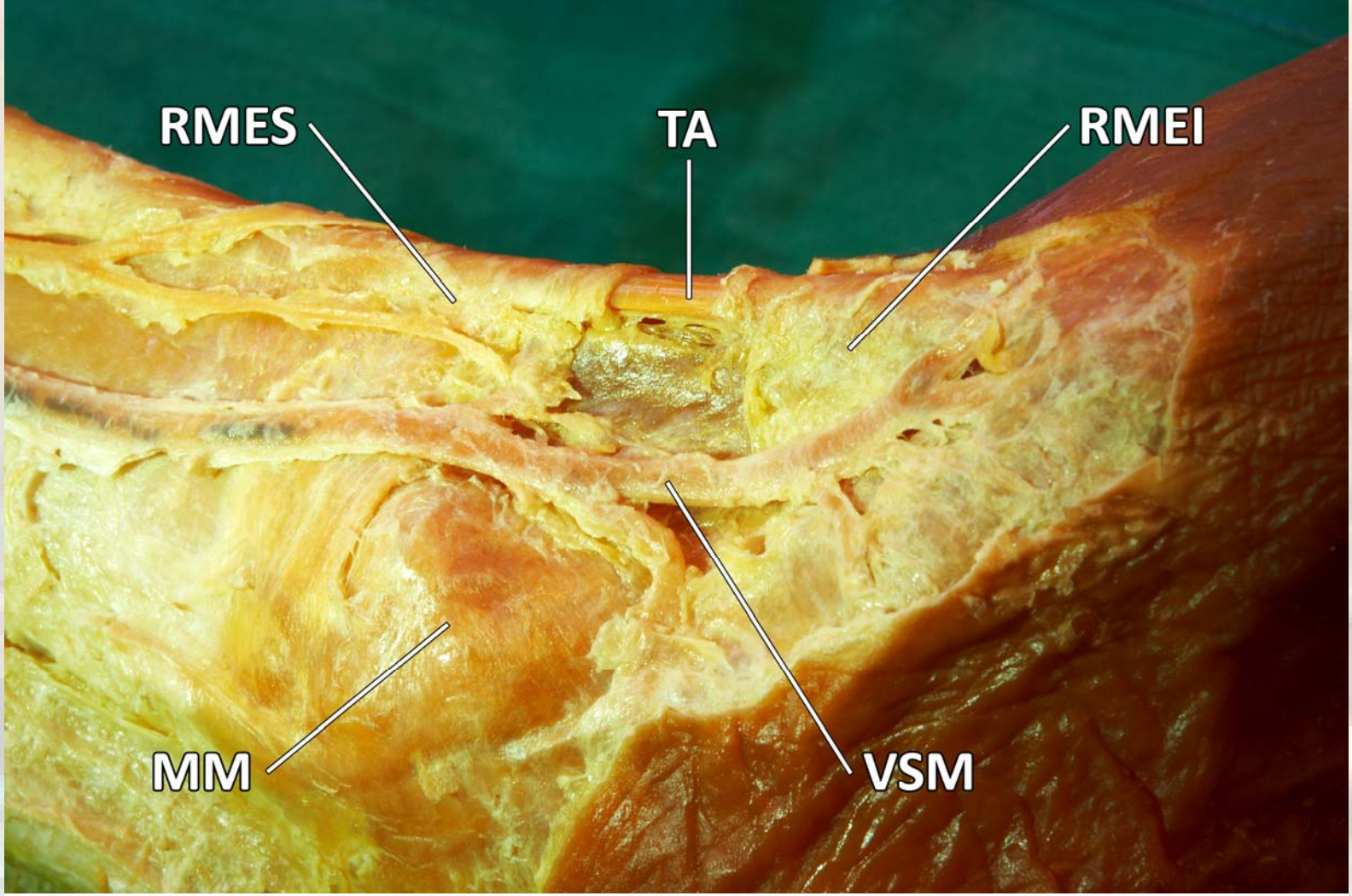

RMES - RETINACULUM MM. EXTENSORUM SUP.
TA - TENDO M. TIBIALIS ANT.
RMEI - RETINACULUM MM. EXTENSORUM INF.
VSM - V. SAPHENA MAGNA
MM. MALLEOLUS MEDIALIS

STRUCTURES IN FRONT OF THE MEDIAL MALLEOLUS

BORDERS:

VENTRAL:
retinaculum mm. extensorum

DORSAL:
malleolus medialis

CONTENTS:

ventrally of retinaculum mm. Extensorum:

vena saphena magna

nervus saphenus

dorsally of retinaculum mm. ext.:

musculus tibialis ant.

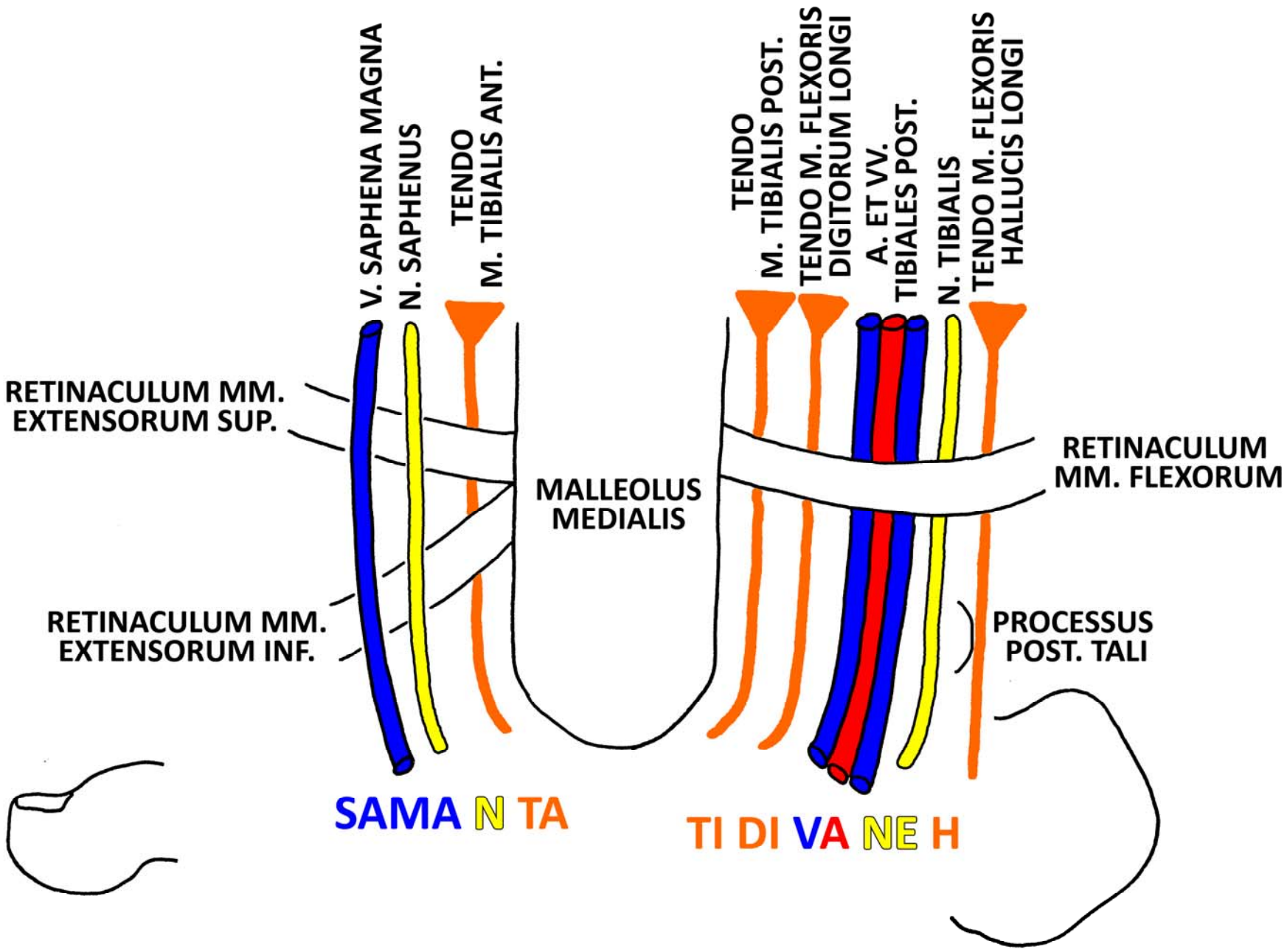
V. SAPHENA MAGNA
N. SAPHENUS
TENDO
M. TIBIALIS ANT.
TENDO
M. TIBIALIS POST.
TENDO M. FLEXORIS
DIGITORUM LONGI
A. ET VV.
TIBIALES POST.
N. TIBIALIS
TENDO M. FLEXORIS
HALLUCIS LONGI
RETINACULUM MM.
EXTENSORUM SUP.
MALLEOLUS
MEDIALIS
RETINACULUM
MM. FLEXORUM
RETINACULUM MM.
EXTENSORUM INF.
PROCESSUS
POST. TALI
SAMA N TA
TI DI VA NE H

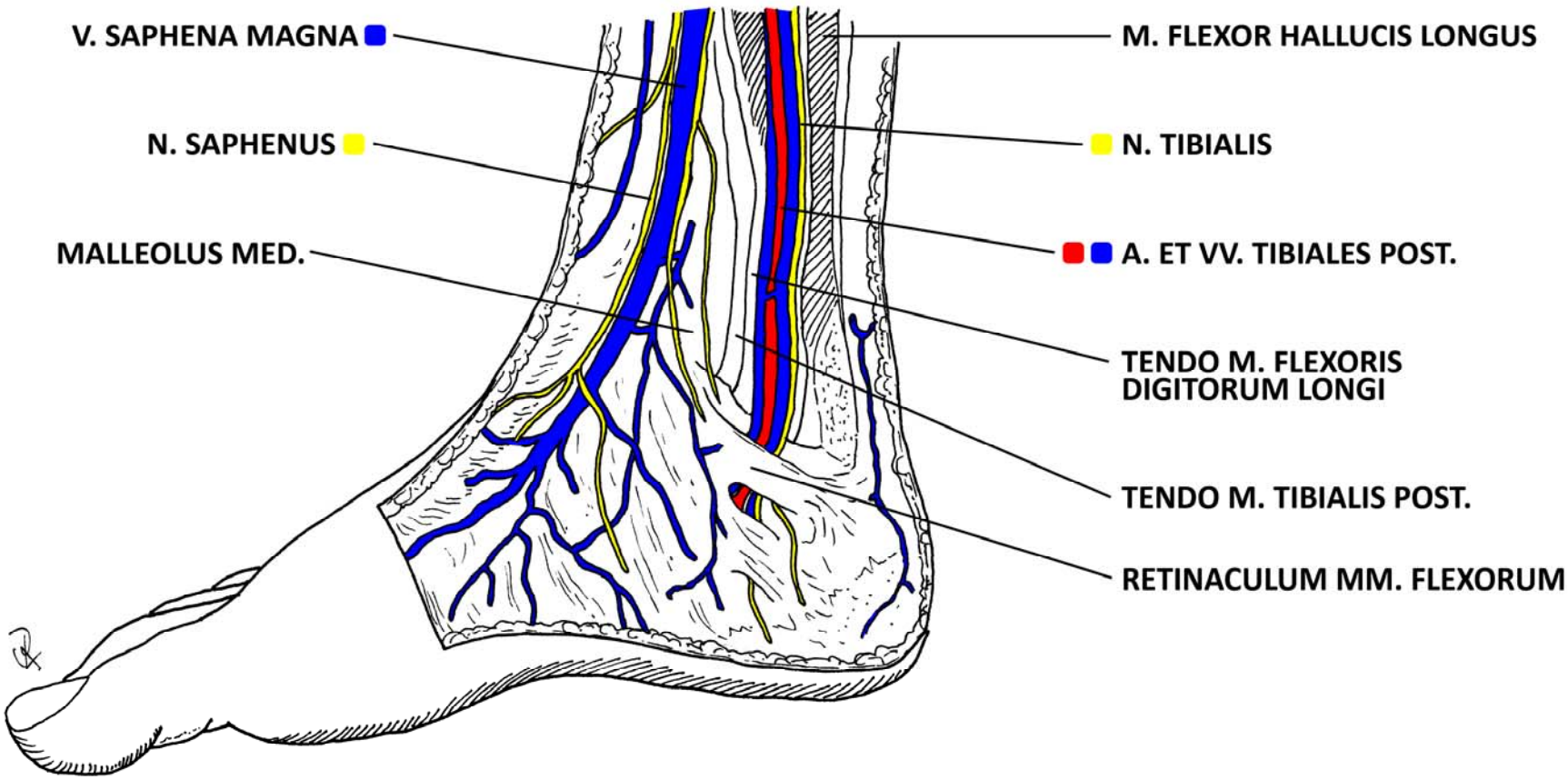
V. SAPHENA MAGNA
N. SAPHENUS
MALLEOLUS MED.
M. FLEXOR HALLUCIS LONGUS
N. TIBIALIS
A. ET VV. TIBIALES POST.
TENDO M. FLEXORIS DIGITORUM LONGI
TENDO M. TIBIALIS POST.
RETINACULUM MM. FLEXORUM

STRUCTURES BEHIND THE LATERAL MALLEOLUS

BORDERS:

LATERAL:
retinaculum musculorum fibularium
sup. et inf.

VENTRAL:
malleolus lateralis

DORSAL:
tuber calcanei

CONTENT:

SUPERFICIAL:
vena saphena parva
nervus suralis

DEEP: *(under retinacula)*
tendo m. fibularis longi et brevis

/in common tendon sheath/

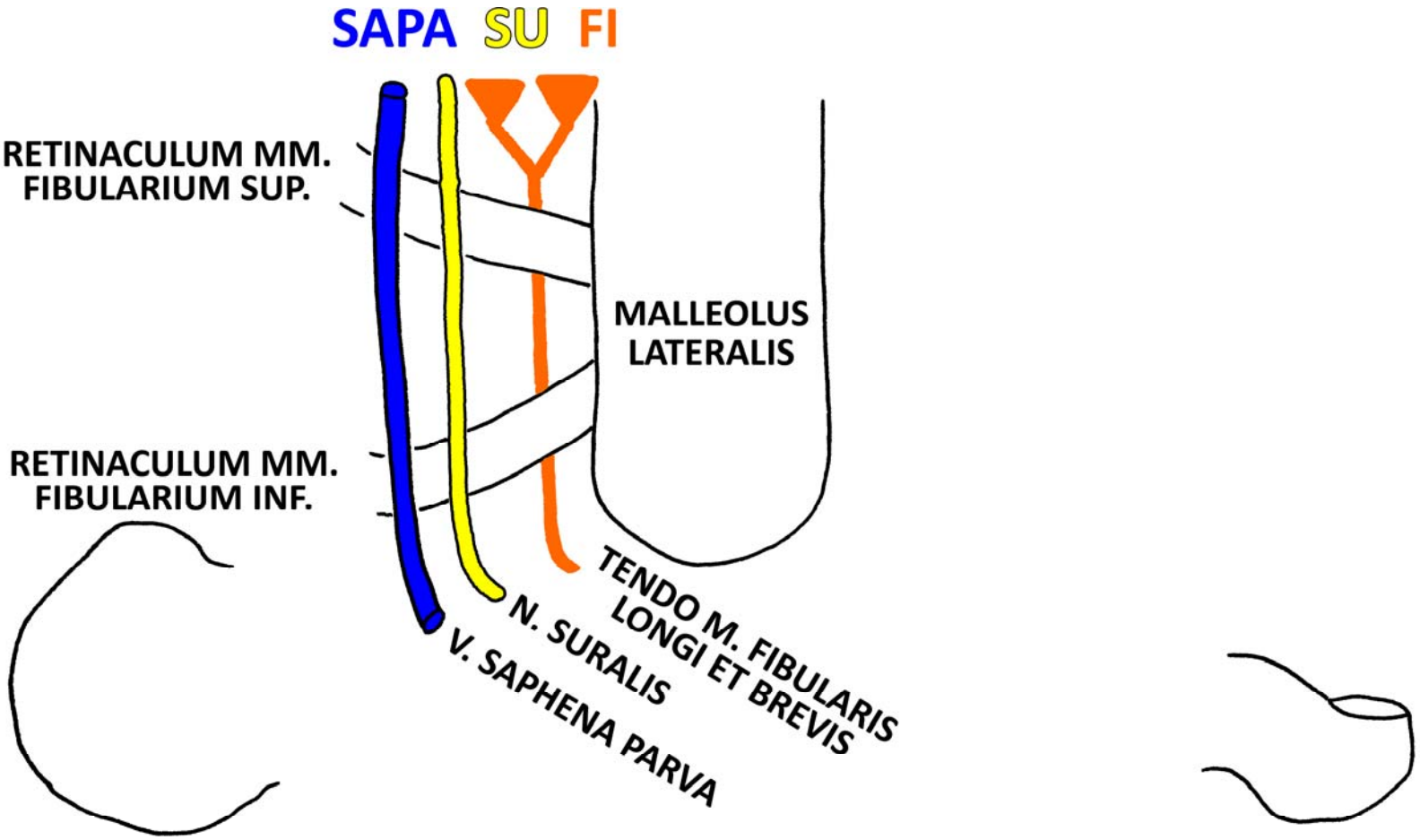
SAPA
SU
FI
RETINACULUM MM.
FIBULARIUM SUP.
MALLEOLUS
LATERALIS
RETINACULUM MM.
FIBULARIUM INF.
TENDO M. FIBULARIS
LONGI ET BREVIS
N. SURALIS
V. SAPHENA PARVA

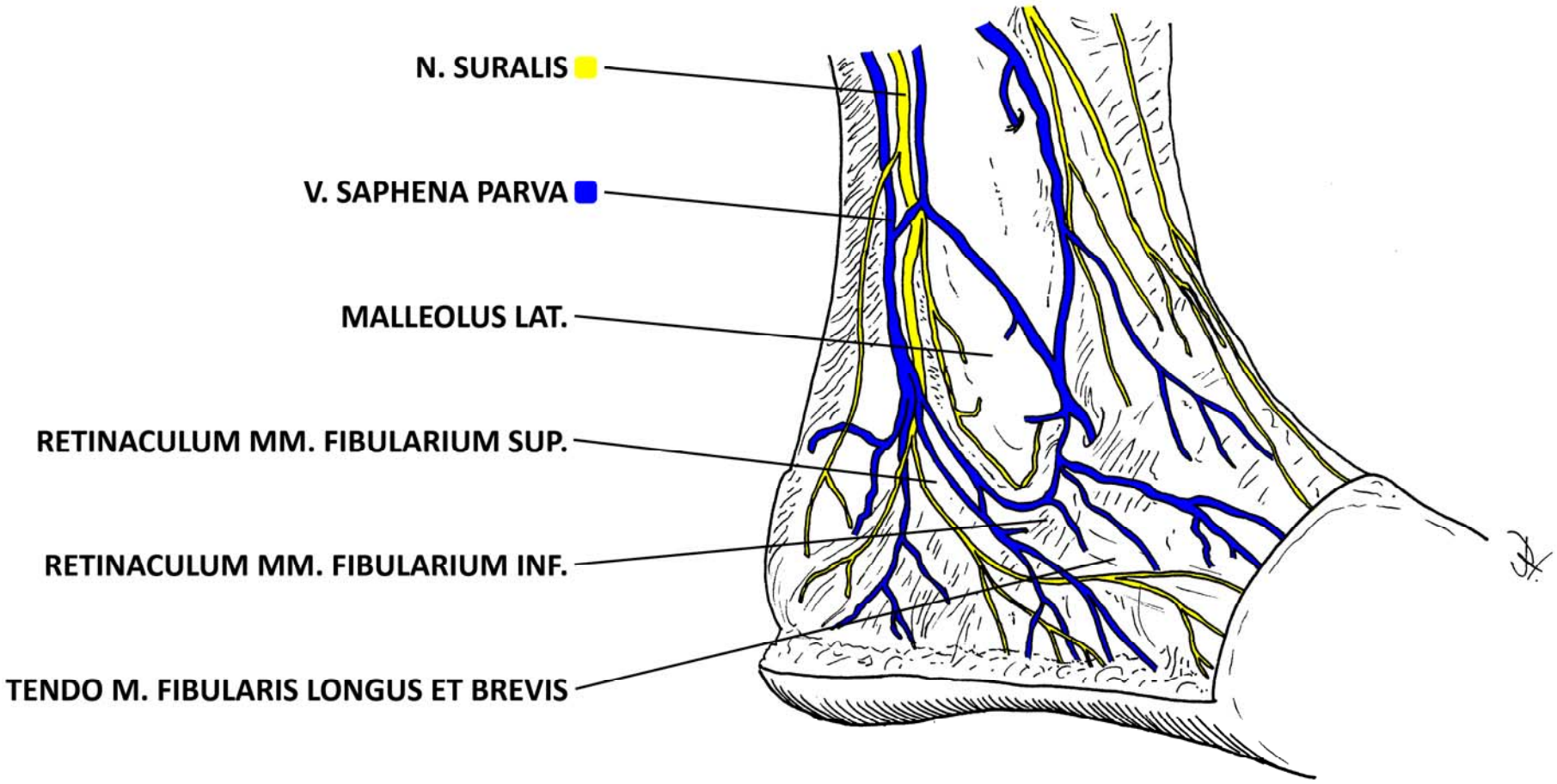
N. SURALIS
V. SAPHENA PARVA
MALLEOLUS LAT.
RETINACULUM MM. FIBULARIUM SUP.
RETINACULUM MM. FIBULARIUM INF.
TENDO M. FIBULARIS LONGUS ET BREVIS

LISFRANK´S JOINT

complex of art. tarsometatarsales and art. intermetatarsales

CHOPART´S JOINT
(art. tarsi transversa)

art. calcaneocuboidea + talonavicular part of art. talocalcaneonavicularis

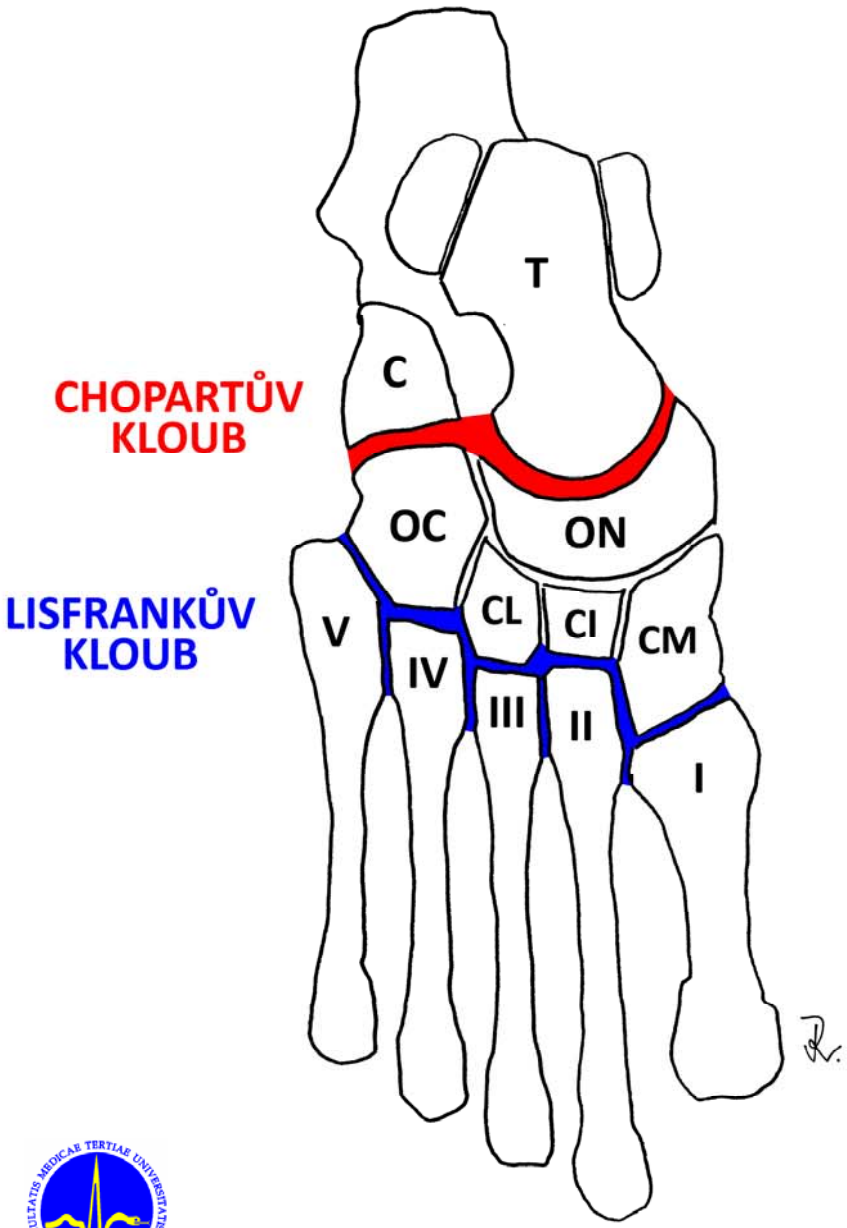

T - TALUS
C - CALCANEUS
ON - OS NAVICULARE
OC - OS CUBOIDEUM
CL - OS CUNEIFORME LAT.
CI - OS CUNEIFORME INTERMEDIUM
CM - OS CUNEIFORME MED.
I - OS METATARSI PRIMUM
II - OS METATARSI SECUNDUM
III - OS METATARSI TERTIUM
IV - OS METATARSI QUARTUM
V - OS METATARSI QUINTUM